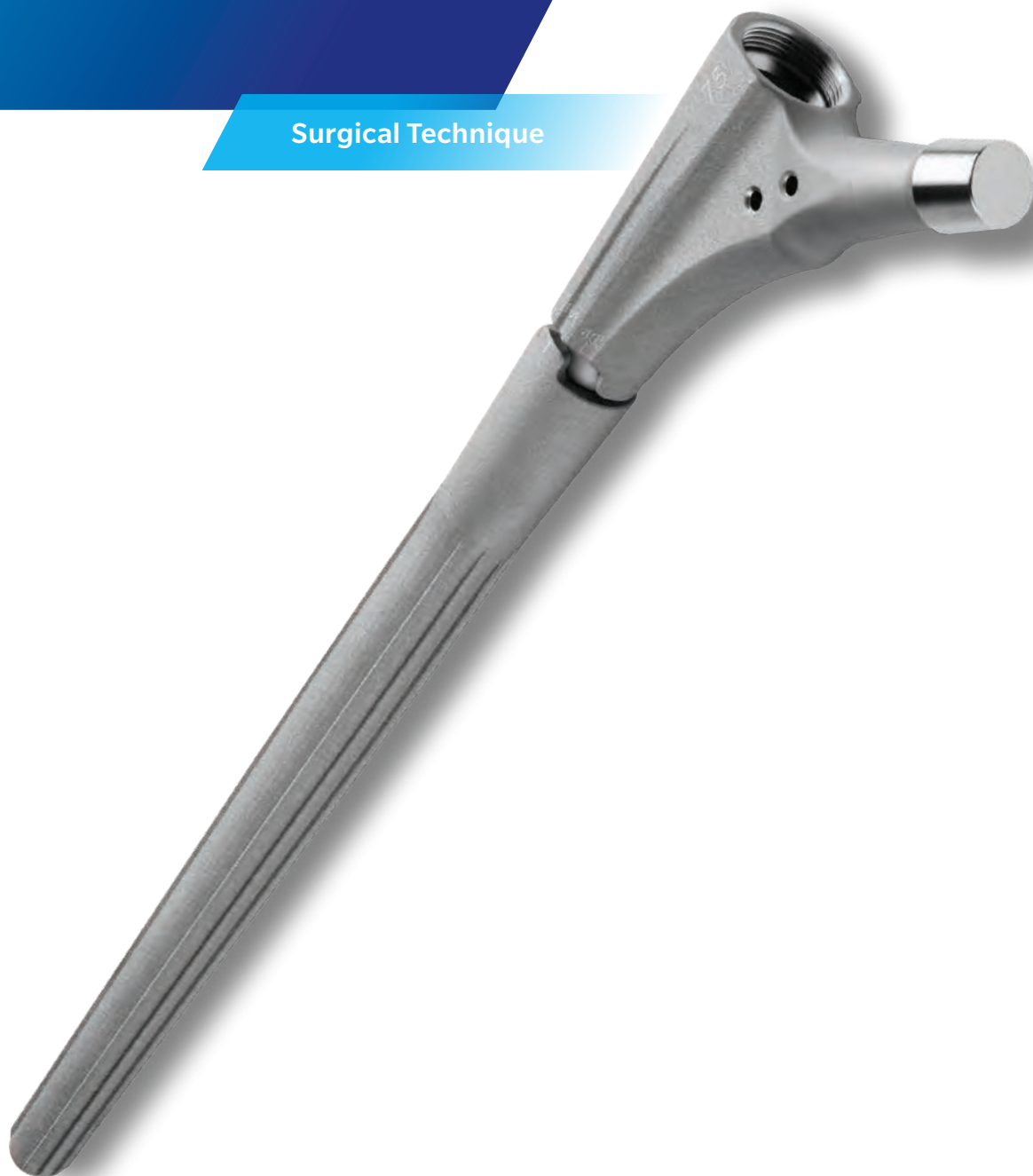

# Revitan<sup>®</sup> Straight

Revision Hip System

Surgical Technique





## Table of Contents

<b>Implants – Concept – Instrumentation</b> .....	2
Implants Description .....	3
Press-fit Concept.....	5
Instrumentation .....	7
<b>Preoperative Planning</b> .....	9
Radiological Analysis of the Femur.....	10
Determining a Surgical Strategy .....	14
Making a Preoperative Template.....	18
<b>Surgical Technique</b> .....	20
Rational Use of the Implants .....	21
Preparing a Bone-Implant Contact Surface .....	22
Ensuring Effective Implant Fixation .....	24
Option 1: Femoral Flap .....	26
Option 2: Endofemoral Approach .....	32
<b>Postoperative Treatment</b> .....	38
<b>Case Studies (Femoral Flap)</b> .....	40
<b>Case Studies (Endofemoral approach)</b> .....	41
<b>Conclusions</b> .....	42
<b>Appendix 1</b> .....	44
Assembly of the Two Implant Components .....	44
Assembly of the Stem in One Stage (Extrafemoral) .....	45
Assembly of the Stem in Two Stages (Intrafemoral) .....	46
<b>Appendix 2</b> .....	47
Removal of a Revitan Straight Stem (PFM-Revision of the first and second generation) .....	47

## Implants – Concept – Instrumentation



### Forward

This document discusses straight, uncemented stems, whose primary stability is achieved exclusively by means of press-fit anchorage. This type of prosthetic implant has been used since 1994 and is called Revitan Straight Stem or PFM-Revision of the second generation (“Prothèse Fémorale Modulable pour Révision” or “Press-Fit Modular Revision Prosthesis”). They have to be differentiated from the other implants that come under the brand name of Revitan, and are characterized as curved stems of more recent manufacture that are essentially not used in the same way as a straight stem.

Straight stems and curved stems are different, and it is important to be aware of these differences in order to avoid complications when choosing a strategy for implantation.

Each implant can be a compromise. Every surgeon should educate themselves and ask questions in order to make the best choice for their patient. The surgeon must be fully aware that each design has its special requirements and advantages and disadvantages.

### Important

The components and instruments of the Revitan Straight system (PFM-Revision of the second generation) cannot be combined with the components and instruments of the first-generation PFM-Revision system.

## Implants – Concept – Instrumentation

### The Implants Description

The Revitan Revision Hip System (PFM-Revision of the second generation) consists of a set of femoral stems made of Ti6Al7Nb titanium alloy (Protasul®-100). Each femoral stem is made up of 2 parts: one proximal component and one distal component. Mechanical coupling is ensured by a Morse taper connection.

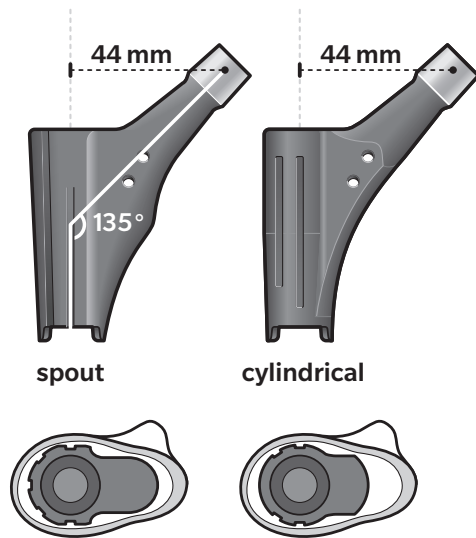


Figure 1 - Spout

The top of female Morse taper is threaded for the impactor and the disassembly instruments for the proximal component.

The offset of 44 mm is a compromise that on one hand ensures a good function of the gluteal muscles and on the other hand avoids excessive stress on the coupling area.

### Proximal Components

There are **2 types** of proximal components: spout or cylindrical. Figure 1, the spout components are wider on the frontal plane whilst the medial profile of the cylindrical components is thicker. Components of 6 different heights are available for each type, in increasing size by steps of 10 mm, from 55 mm to 105 mm. The CCD angle is 135° and the offset is 44 mm.

The lateral side with ribs and grooves is hollow, i.e. featuring the female part of the Morse taper connection. There are two holes in the medial part that can be used for nonmetallic suture to reinsert a flap.

### Distal Components (Figure 2)

The distal component is available in three different lengths: 140, 200 and 260 mm. In addition to this range, a 120 mm stem (diameter 14 mm) is also available. This corresponds to a 140 mm stem that has been shortened by 20 mm.

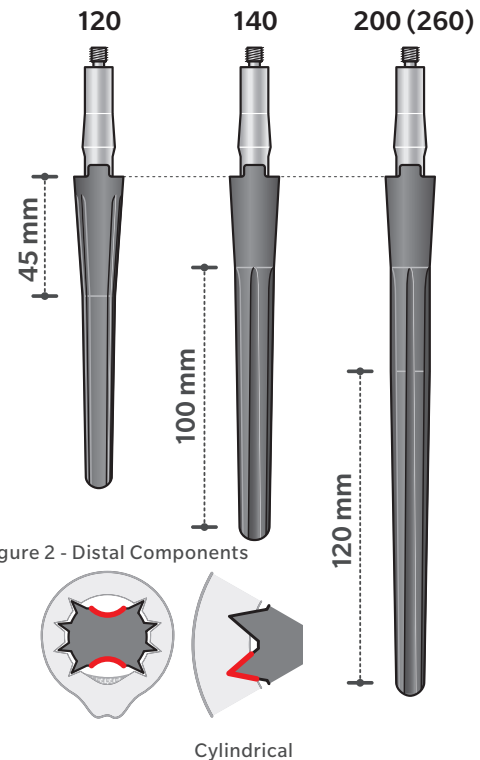


Figure 2 - Distal Components

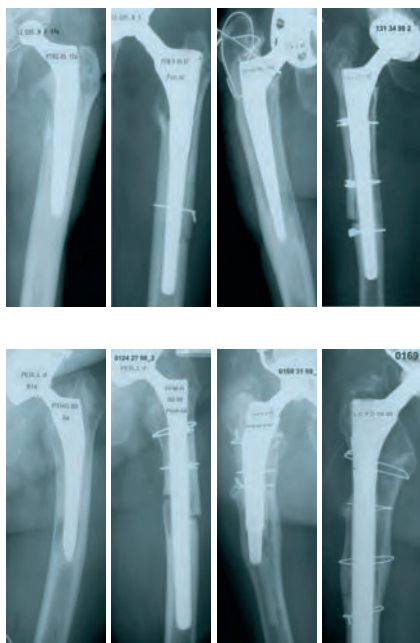The conical part of the implant is always in a distal position. The greater the slope of the conical part, the shorter the conical part will be and the weaker the distal part of the implant. The slant of 2° of the conical part means that this part is sufficiently high without excessive weakening of the distal part of the stem, even for those with the smallest diameters (14 and 16 mm).

The fins are also conical in shape, which seems to us to be preferable to a vertically grooved design, which would be less effective, or to blade-shaped fins, which would be weaker.

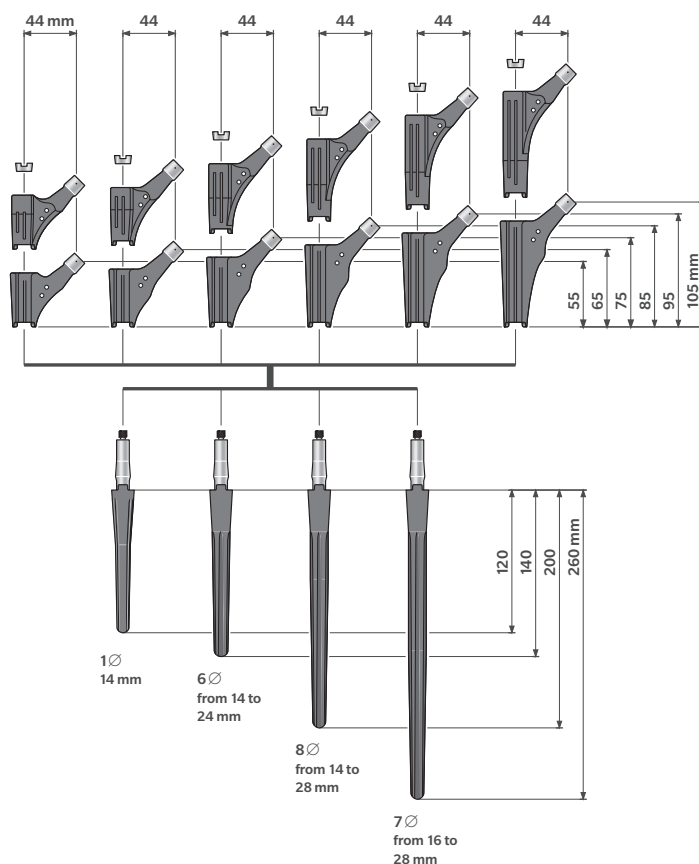
The diameter increases by steps of 2 mm from 14 to 28 mm. The whole range includes a total of 16 components. They are **straight** stems with 8 longitudinal ribs and, from the size of diameter 18 mm, each stem has a flattened anterior-posterior area, with increasing size as the diameter increases.

The shape of these implants is **conical**, with a taper of 2°. The height of the conical area is 100 mm for the 140 mm stems, whereas it is 120 mm for the 200 and 260 mm stems.

The working area of this implant is the conical proximal area, which is 45 mm high with a cone of 9°, with lateral ribs.



Sizes – Possible combinations



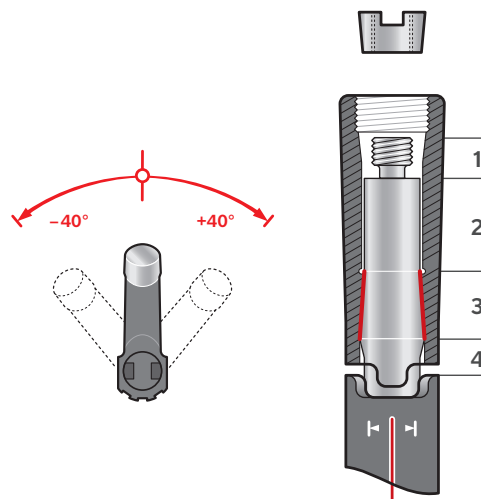
## The assembly system

The two parts of the prosthesis are coupled together by means of an original and efficient Morse taper system perfected in 1989 and used since then successfully in clinical application. The Morse taper has 4 areas:

1. Thread for the conical nut
2. Cylindrical area for the centering of the 2 components.
3. Conical area for mechanical coupling.
4. Area of a narrower cross section, allowing concentration of stresses at this level.

Before the assembly: It is possible to adjust the antetorsion of the proximal component from  $+40^\circ$  to  $-40^\circ$ .

After the assembly: A gap of about 1 mm between the 2 components enables micromovements without inducing the formation of any metal debris.



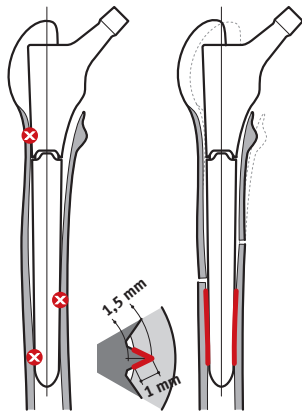
**Note:** The entire set of components making up the Revitan Straight System (PFM-Revision of the second generation) is modular. Proximal spout components with a height of 55 to 85 mm and the distal components with length of 140 mm are most widely used. Distal components with a length of 260 mm are very rarely used.

## Implants – Concept – Instrumentation

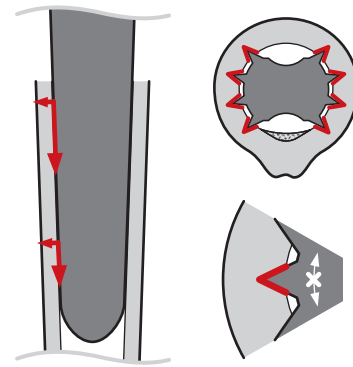
### The Press-fit Concept

The press-fit concept is an assembly process consisting of the fitting of 2 separate parts, used frequently in the industry (Morse taper systems). It is also a good technique to ensure the primary stability of a femoral revision stem in the bone. This was the technique selected by Wagner in 1987. The prerequisites to ensure the press-fit surgically were very well defined by Morscher: First of all, achieve a contact surface between the bone and the implant, then ensure that the prosthesis is perfectly wedged into place, and lastly, avoid excessive stiffening of the femur. To achieve these three objectives, a press-fit stem requires very specific geometrical characteristics. It should be stressed here that, while the modular concept does not, as such, ensure the primary stability of an implant, it is a good means for obtaining an effective press-fit.

**Note:** The Revitan System is not designed for use in a fully unsupported proximal femur. Bone stock of adequate quality must be present and appraised at the time of surgery. For patients with severe proximal deficiency, a surgeon should consider surgical options to ensure proximal bone support (such as medial and/or lateral strut grafts) or switching to a monobloc revision stem.



A curved stem is straight in the frontal plane since the curvature of these implants can only be used in one plane. This means that when the femur is curved in the frontal plane, a femoral osteotomy is necessary, as in the case of a straight stem.



In order to be wedged into place, a cylindrical stem would have to be slightly oversized with respect to the medullary canal; this entails several drawbacks, like difficulties during placement (stress peaks), risk of fracture if the cortical bone is fragile, uncertain rewedging if the initial wedging was not perfectly successful.

The cross section of a press-fit stem also has to be carefully considered, since control of rotational stresses depends to a great extent on this cross section. We believe that a finned stem has a definitive advantage in this respect, whereas a circular cross-sectioned stem with a generally quite smooth surface does not provide a high resistance to the rotational stresses.

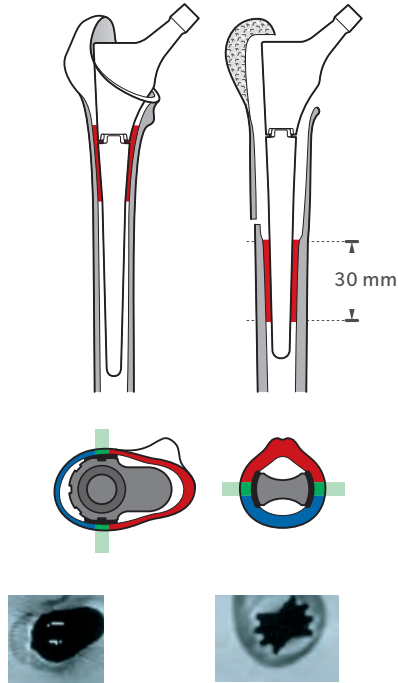
### Bone-implant contact surface

A **straight stem** is a good way to achieve a large enough surface contact between bone and implant. The longitudinal ribs enlarge the contact surface if their penetration into the cortex is sufficient.

In order to achieve this aim with a straight stem, **a three-point support must be avoided**. This means that in the case of a straight femur in the frontal plane, implantation in the varus position is to be avoided, and in the case of a curved femur, a femoral osteotomy is necessary. A three-point contact on the sagittal plane may result in the choice of an undersized prosthesis, which will impede bone-implant contact on the frontal plane.

### Ensuring that the implant is firmly wedged in place

This means ensuring the primary stability of the implant by creating a higher stress (or prestress) at the height of the bone-implant interface than the destabilizing forces consisting of axial and rotational stresses. A **conical stem** features the best design to ensure a secure wedging: progressive transformation of the vertical shear stress into stabilizing horizontal stress, with a more even distribution of the forces and the possibility of rewedging. A stem with ribs facilitates wedging (easier impaction) and ensures excellent rotational stability, which is essential for an uncemented stem.



The neutral zone is located at the intersection of the traction and compression areas. It is on a sagittal plane in the proximal area of the femur and on a frontal plane in the diaphyseal region.

To achieve the aims indicated earlier, a press-fit stem must fulfill some very specific requirements: the metaphyseal part must have a wide profile or a steep conical slant in order to optimize contact between the bone-implant in the sagittal plane. In the diaphyseal region it is necessary to avoid circular contact (in particular on the sagittal plane) so as to ensure bone-implant contact in the frontal plane. In such conditions, the ribs must be placed on this plane only.

## Avoid-excessive stiffening of the femur

In order to lower the risk of stress-shielding. To achieve this, it is necessary to comply with 3 rules:

- **Try to achieve proximal fixation of the implant** whenever it is possible. If the femur is straight on the frontal plane, fixation in the metaphyseal-diaphyseal region is frequently possible.
- **Limit the height of the bone-implant contact area** when diaphyseal fixation only is possible. The primary stability of a press-fit stem can be achieved over a distance of approximately 3 cm.
- **Avoid filling the medullary canal too much** in order to conserve transmission of the stresses (traction and compression). To achieve this, limit bone-implant contact in the vicinity of the neutral zone of the femur.

## Conclusions

Often mentioned for securing the primary stability of uncemented implants, the press-fit is a concept which is often misunderstood; in such conditions, the risk of poor practical application is also considerable.

When selecting the press-fit concept, it is necessary to choose an implant having well defined features with the only objective to meet the requirements that this method of fixation requires. We believe that a ribbed straight stem with a conical shape is a good choice.

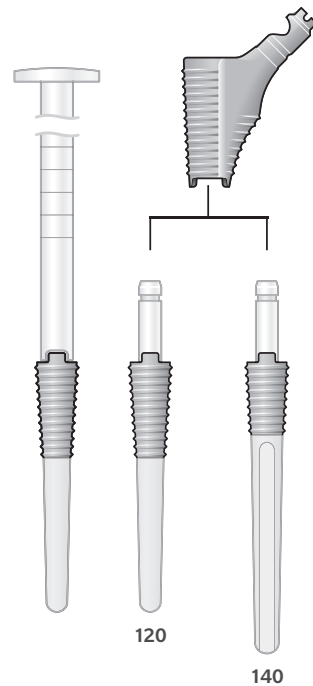
As a general rule, if an uncemented stem is chosen for revision surgery, the design of the implant must always be considered carefully, and it is advisable to be wary of implants which combine multiple concepts. Most of these prostheses do not have the right characteristics for applying the various concepts proposed, particularly the press-fit, with due rigor. Also, it is advisable to be wary of stabilizing implants owing to their length, as this requires the surgeon to implant a stem that is longer than necessary.



## Implants – Concept – Instrumentation

### The Instrumentation

The instrumentation consists of a set of reamers, a system of rasps and modular test prostheses, and a proximal trial part enabling the definitive prosthesis to be implanted in 2 stages. Although the rasps and test prostheses are combined in a single instrument, it is suggested to consider it as two distinct instruments, as its function varies depending on the option chosen by the surgeon. For the reamers refer to Surgical Technique: Preparing a bone-implant contact surface.



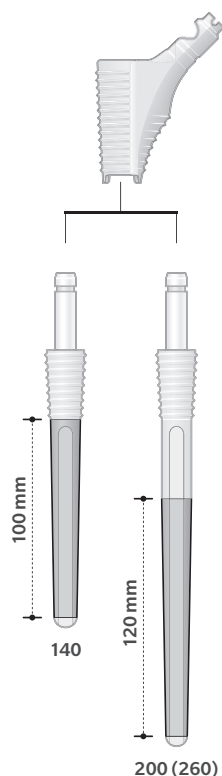
A modular rasp enables a two- stage preparation of the femur. For this purpose, the surgeon disposes of a rasp adaptor used to drive in the distal rasp and to choose in a second step the size of the proximal rasp (graduated from 55 to 105 mm). Refer to Surgical Technique: Preparing a bone-implant contact surface.

Although the rasp does include the 200 and 260 mm distal components, we believe that it is of lesser use for these implants. Indeed, when proximal fixation is sought, these implants are too long and they should not be used in that case. The use of a long stem is recommended only when a femoral flap is performed.

### Modular Rasps

- The rasp function is only used if the endofemoral approach is selected, with proximal fixation in the metaphyseal-diaphyseal area. In this situation, the rasp also is used as a test prosthesis.
- The rasp involves the whole range of proximal components (spout and cylindrical). For the distal components, the rasp is limited only to the 120 mm long component and to 140 mm long distal components with diameters of 14 to 18 mm.

The use of an implant with a diameter of 20 mm or larger (L 140 mm) means that only diaphyseal fixation can be achieved. In that case the preparation of the femur is done with a reamer whose diameter is superior to the size of the proximal components, making the rasp ineffective.

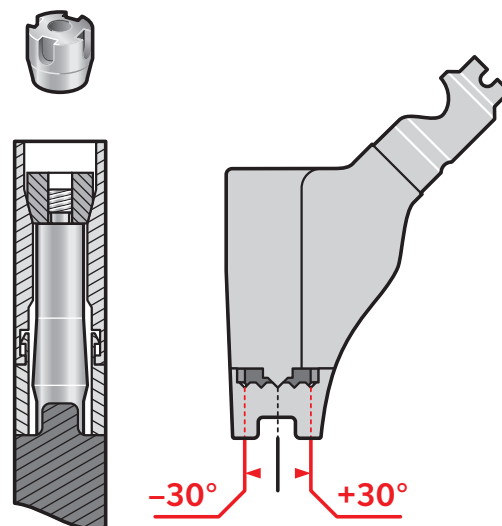


When press-fit is selected in order to ensure primary stability, the role of a test prosthesis is essential. Having a modular test prosthesis enables stability to be ensured by the conical area of the implant. Refer to the surgical technique: Ensuring that the implant is wedged into place.

## Modular test prostheses

When fixation of the implant is achieved in the diaphyseal region, the femur is prepared with the reamers. In this case, the rasp is no longer necessary, and only the test prosthesis function is of use. Primary stability is ensured with the smooth conical area of one of the distal components 140, 200, or 260 mm in length (the conical area is demarcated by 2 transversal lines). The proximal components serve to adjust the length of the lower limb.

The 140 mm distal components can be used both as rasps and as test prostheses.



This instrument set can only be used when a femoral flap has been completed. In this case, it is essential to ensure that the distal component of the definitive prosthesis wedges perfectly into place.

## Proximal trial part

These instruments enable the definitive stem to be implanted in two stages.

There is a proximal trial part corresponding to each definitive proximal component. It is assembled to the distal component by means of a nut screwed to the threaded part of the Morse taper without any contact with the Morse taper. It is possible to adjust its antetorsion by  $\pm 30^\circ$ .

## Summary

The choice of a modular implant implies a modular instrument set, and each definitive implant size must correspond to a test prosthesis.

## Preoperative Planning

Limiting the preparation of a revision surgery when creating a simple template, in other words, choosing an implant that adapts to the endomedullary canal of the femur in its current state, is just the opposite of what should be done, namely: adapt the bone context to the selected concept.

Each concept has its own imperatives. A good knowledge of the objectives to be achieved in order to ensure primary stability is essential for defining a rational and logical surgical strategy.

☰ **Note:** Revision surgery with a press-fit concept implant is prepared in three stages: radiological analysis of the femur, determining a surgical strategy, and making a preoperative template.

### Radiological Analysis of the Femur

A preoperative X-ray planning as described here has the purpose of defining a surgical strategy aimed at avoiding any worsening of the bone lesions and at enabling to get to the objectives imposed by the press-fit concept so as:

- to achieve bone-implant contact as a surface, which means that it is necessary to evaluate the extent of the defects and the presence of any curvature of the femur to avoid a three-point contact of the implant.
- to ensure that the prosthesis is wedged perfectly into place, which depends mainly on the surgical technique but also implies the need to be in close proximity to the fixation area.
- to avoid stiffening the femur. This objective depends on the design of the implant but also on the possibility to achieve proximal or short diaphyseal fixation, which depends on the morphotype, on the extent of the defects, on the quality of the cortical bone, and on the

appearance of the medullary canal.

It is necessary to differentiate between X-ray images aiming to choose a surgical strategy and those aiming at the evaluation of the long-term clinical results. This distinction has to be made as long as the important criteria to ensure a safe surgery do not influence the evaluation of the results (deviations of the femur or difficulties in removing the cement).

In order to carry out a thorough and complete radiological analysis of the femur, it is necessary to dispose of high-quality X-ray images: An anterior-posterior view of the hip (centered on the loosened prosthesis), an anterior-posterior view of the pelvis, and anterior-posterior and lateral X-ray images of the femur extending up to 15 cm below the distal end of the loosened stem are required.

These four X-rays are the minimum requirements for defining a surgical strategy with some degree of rigor.

### Determining a Surgical Strategy

Determining a surgical strategy means selecting an approach to the femur to overcome the eventual obstacles observed during the examination of the X-rays. This choice determines the area where primary stabilization (the bone-implant contact) will occur.

### Making a preoperative template

Highlight the main obstacles found while analyzing the X-rays of the femur and finally define the strategy. The template also enables to measure the major references that can be used during surgery (length of the flap).

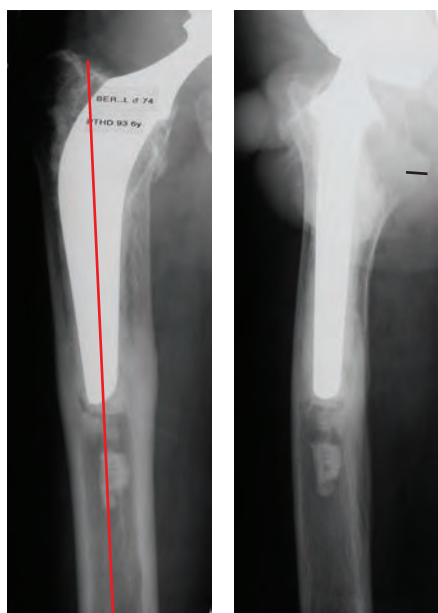## Preoperative Planning

### Radiological Analysis of the Femur

The instrumentation consists of a set of reamers, a system of rasps and modular test prostheses, and a proximal trial part enabling the definitive prosthesis to be implanted in 2 stages. Although the rasps and test prostheses are combined in a single instrument, it is suggested to consider it as two distinct instruments, as its function varies depending on the option chosen by the surgeon. For the reamers refer to Surgical Technique: Preparing a bone-implant contact surface.

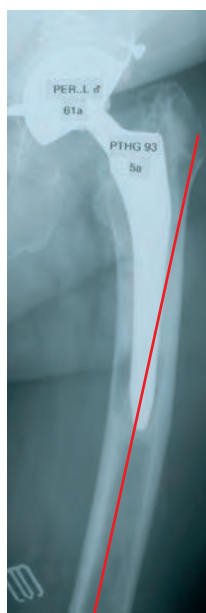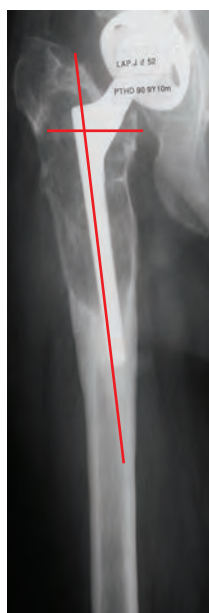#### 1 – Femur straight in the frontal plane

In the sagittal plane: curvature not pronounced.

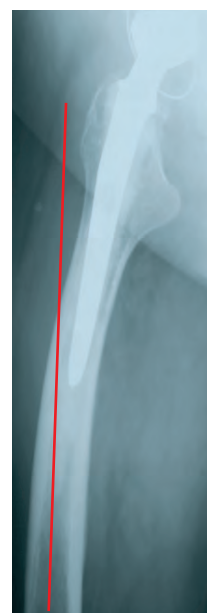
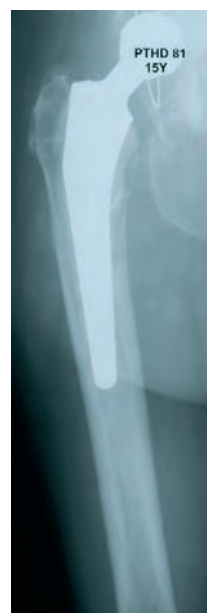
#### 2 – Femur curved in the frontal or sagittal plane

Curvature in the frontal plane, regardless of its extent.



Sagittal: pronounced curvature (overall) and straight in the frontal plane.



### Morphotypes

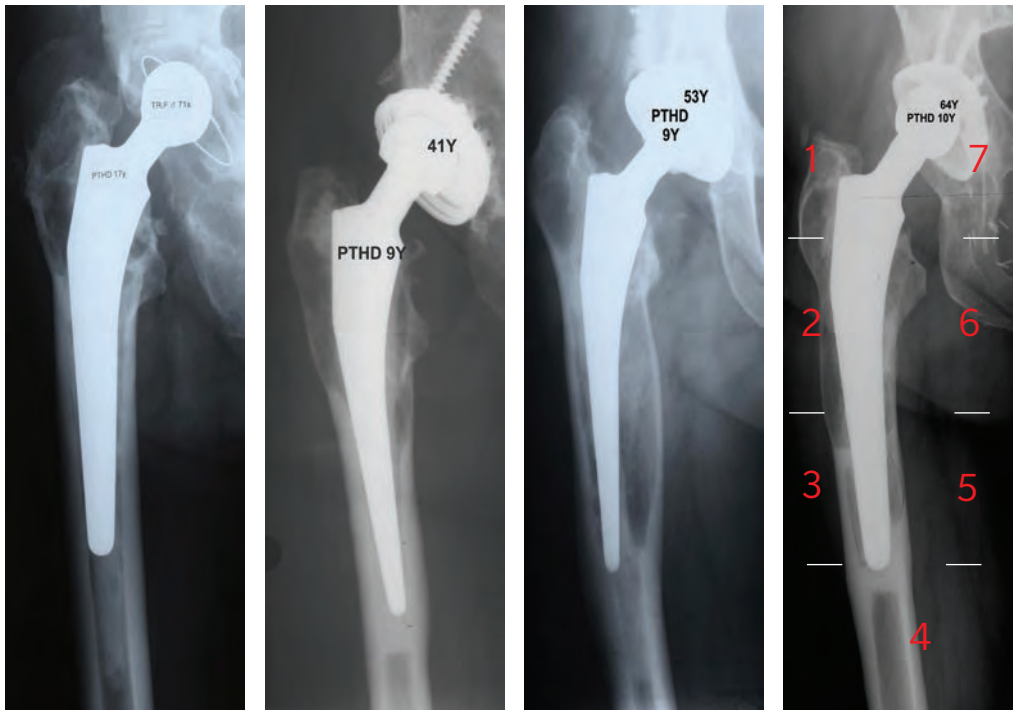
Evaluate the presence or not of a curvature in the frontal plane and the extent of the curvature in the sagittal plane. This verification is very important if a straight stem and the press-fit concept have been selected.

An anterior-posterior X-ray and a lateral-view X-ray will be required, showing the femur up to about 15 cm below the distal end of the loosened implant. The templates of a long stem must be used.

Valgus deviations in the frontal plane are rare, while varus deviations are frequent. It is therefore always wise to consider a curvature of the femur in the frontal plane, even if it is not pronounced.

In the sagittal plane, the femur is rarely straight and a slight curvature or a double sagittal curvature (diaphyseal curvature with posterior concavity compensated by a proximal curvature with anterior concavity) need not be taken into account since this is usually not an obstacle to place a straight stem.

Overall curvature means a diaphyseal curvature with marked posterior concavity not compensated by a proximal curvature with anterior concavity.



**Stage 1**  
Absent defects  
or area(s) 1 and/or 7

**Stage 2**  
Defects in zone(s)  
2 and/or 6  
No defects in areas 3 and 5

**Stage 3**  
Diaphysis defects:  
1 cortex  
Area 3 or 5 affected

**Stage 4**  
Diaphysis defects:  
2 cortex  
or fracture around the stem

## Defects

Evaluate all lesions resulting in a fragile cortical bone in the area of the femur with the implant (granulomas, stress-shielding or osteoporosis, mechanical wear). Evaluate the lesions on the basis of their sizes (Gruen's areas).

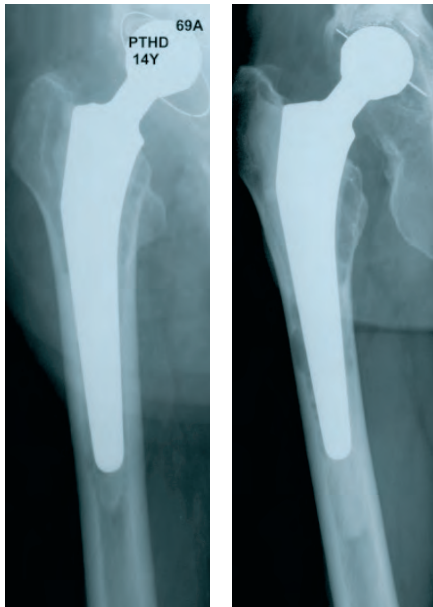The following examples refer only to lesions caused by granulomas.

**Note:** In this classification, the femoral isthmus (Area 4) is present and can be used to provide primary stability. Otherwise the situation at hand is a particular one (see pages 18 and 19).

For stage 2, include lesions affecting an area of the diaphysis other than areas 2 or 6.

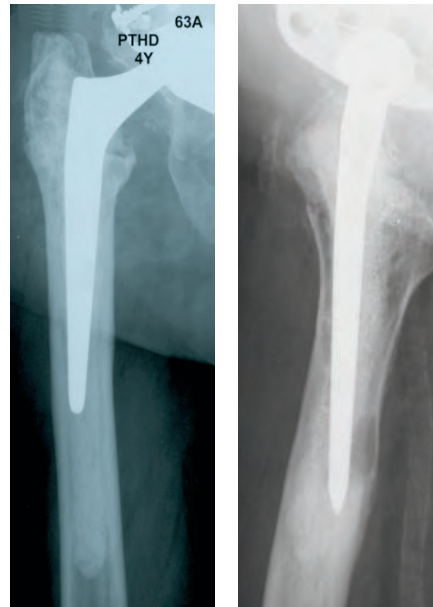For stage 3, include isolated granulomas in area 4 or, if they are aggressive, at a distance.

For stage 4, include fractures around the stem regardless of the condition of the cortex elsewhere. Defects due to stress-shielding or areas weakened by osteoporosis usually affect the cortical bone on both sides and in most cases are therefore classified as stage 4.



#### 1 – No difficulties

No plug or < 3 cm and good cortex.



#### 2 – Presence of difficulties

Plug > 3 cm if good cortex.

Thick cement or plug < 3 cm or off-axis with fragile cortex +.

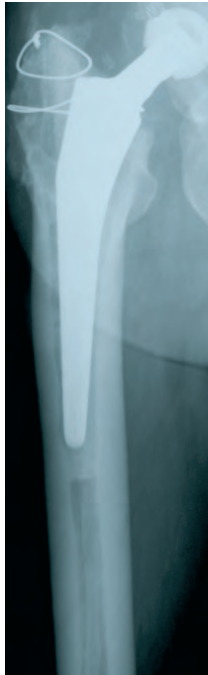## Cement

It is suggested to analyze the cement mantle entirely. The evaluation of the difficulties to remove the cement should not be limited to the presence or not of a distal cement plug; the thickness of the cement should also be assessed, considering the quality of the cortical bone on both sides.

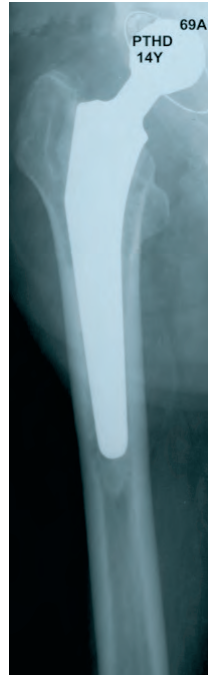The challenges of removing uncemented implants should also be considered along with those faced in removing cement, especially when the implant is not loose.

**Note:** If the intermediate cement is thick and well adhering to fragile cortical bone on both sides, the risk of a malpositioning is significant. The same applies if the distal end of the stem is off axis frontally or sagittally.

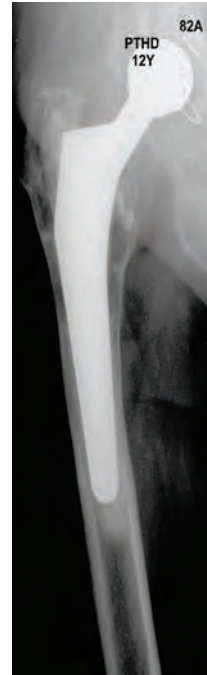




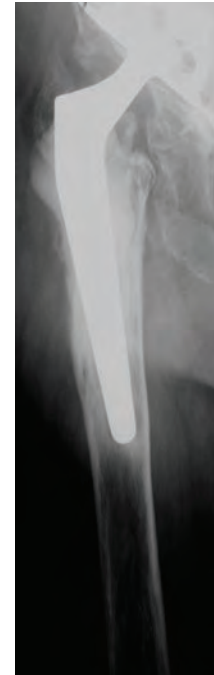
**1 – Excellent**  
Thick cortex ++  
Conical medullary canal  
CI  $\geq 0.55$



**2 – Good**  
Thick cortex ±  
Conical medullary canal ±  
CI 0.45 to 0.54



**3 – Mediocre**  
Thin cortex ±  
Cylindrical medullary canal ±  
CI 0.35 to 0.44



**4 – Poor**  
Thin cortex +  
Wide medullary canal +  
CI  $\leq 0.34$

## Degree of osteoporosis

Carry out this evaluation along an area of the femur without implant on an anterior-posterior X-ray, showing the femur over a sufficient length.

Evaluate the thickness of the cortical bone and the geometry of the medullary canal: conical or cylindrical and, in some cases, measure the thickness of the cortex as a cortex index (CI).

To differentiate between intermediate stages 2 and 3, give priority to the geometry of the medullary canal. If it is cylindrical, it should be classified as stage 3 even if the bone cortex is not particularly thin.

The term conical medullary canal can refer to a medullary canal that can be prepared into a conical shape while using the conical reamers (thick cortex); similarly, a cylindrical medullary canal can refer to a medullary canal where it is difficult to prepare in a conical shape with the reamers (thin cortex).

These four parameters are not of equal importance. If a straight stem and the press-fit concept have been selected, a hierarchy is necessary.

### Priority parameters

- The morphotype, because the presence of a femur curved in the frontal or sagittal plane is always an obstacle to the preparation of a large enough surface contact between bone and implant, regardless of whether the stem is straight or curved.

- Bone defects, in order to choose the femur area in which it is possible to ensure primary stability (proximal femur or diaphyseal), or to determine if bone damage is such that stabilizing the implant in the isthmus area is impossible.

### Secondary parameters

- Difficulties in removing the cement. Even though complete excision of the intermediate cement is crucial if a cementless implant is chosen, this parameter is usually taken into consideration when two different strategic choices are being weighed.
- Osteoporosis. This parameter can affect the choice of the femoral approach and the area of primary stability, and in stage 4 osteoporosis, placing a press-fit stem may be contraindicated.

The combination of the four parameters used for the radiological analysis, together with their binary classification (curvature of the femur and difficulty of removing the cement) or their classification in four stages (bone defect and degree of osteoporosis), makes it possible to discern 6 Homogenous Radiologic Groups (HRG) that can be used as a reference in choosing a surgical strategy (see pages 15 and 16).

## Preoperative Planning

### Determining a Surgical Strategy

Determining a surgical strategy consists in an initial choice of an approach to the femur to overcome the various obstacles identified during the radiological analysis, without ignoring the objectives imposed by the press-fit concept. The area of the femur where primary stability of the implant will be achieved depends on this choice.

#### Femoral approach(es)

It is possible to opt either for the endofemoral approach or a femoral flap. This choice depends on the quality of the cortical bone and especially whether there is curvature of the femur.

**Reminder:** varus deviations of the femur are frequent in cases of implant loosening.

#### Fixation area(s) (bone-implant contact)

- If an endofemoral route has been chosen, fixation in the metaphyseal-diaphyseal area or in the proximal diaphyseal area will be sought.
- If a femoral flap is carried out, fixation can only be diaphyseal, in the isthmus of the femur. Try a short diaphyseal fixation (bone-implant contact over a height of approximately 3 cm).  
More rarely, diaphyseal fixation will be used (bone-implant contact over a height of approximately 6 cm).

#### The various options

(see summary table below)

There is a strategic option for each Homogenous Radiologic Group (HRG):

**Option 1** (endofemoral approach and proximal fixation) and **options 3 and 5** (femoral flap and diaphyseal fixation) are the primary options.

**Options 2 and 4** are intermediate options, in which the choice between the endofemoral approach and a flap is open to discussion.

**Option 6** is a special option and is only indicated for a small amount of patients. However, it is worthwhile to highlight it separately, since, in this case, the choice of a press-fit stem may be impossible or contraindicated.





Radiological analysis				Radiological synthesis
Morpho-type	Degree of osteoporosis	Defects	Cement	Homogeneous Radiologic Groups (HRG) – Strategy options
Frontal plane femur straight (1) (1) Profile: straight or slightly curved	Stages	Stage 1	Yes	<b>HRG 1.</b> Propitious situation: femur straight in the frontal plane and slightly curved in the sagittal plane. Absence of any bone defects or localized onto zone(s) 1 and/or 7 (no defects onto zone(s) 2 and/or 6.) The only obstacle could be the possible difficulties in removing the cement: plug or thick layers (sagittal plane) adhering to fragile cortex (osteoporosis stage 3).
			No	
	1 – Excellent	Stage 2	Yes	<b>HRG 2.</b> Intermediate option characterized by a femur straight in the frontal plane with defects onto zone(s) 2 and/or 6, often combined with defects onto zone(s) 1 and/or 7, but no lesion onto zone 3 or 5. In this case, evaluate the extent of the defects onto zone(s) 2 and/or 6 and consider any difficulties in removing the cement: plug or thick layers (sagittal plane) or stem off axis with fragile cortex (osteoporosis stage 3 or stress shielding).
			No	
	2 – Good	Stage 3	Yes	<b>HRG 3.</b> In this situation, the femur is straight but there are defects leading to a weakening of one or both cortices with in any case lesions of the cortex onto zone(s) 3 and/or 5. It is often a granuloma but also can be, in rare cases, an abrasion of one or both cortices due to abnormal mobility of the cement-implant block. When this fragility is due to stress-shielding or osteoporosis, there are usually lesions on both sides of the cortical bone.
			No	
	3 – Mediocre	Stage 4	Yes	<b>Attention</b> In this situation, the femoral isthmus can be used, if this is not already the case (advanced osteoporosis ++ or bone destruction ++) see option 6.
			No	
Frontal or sagittal plane femur curved (2) (2) Profile: overall curvature	Stages	Stage 1	Yes	<b>HRG 4.</b> Intermediate situation which only concerns slight curvatures in the frontal or sagittal plane (1) without defects in areas 2 and/or 6. In this case, the difficulties in removing the cement should be thoroughly assessed while considering the quality of the cortical bone on both sides.  (1) If the curvature in the frontal or sagittal plane is pronounced, a femoral flap is almost always necessary (See option 5)
			No	
	1 – Excellent	Stage 2	Yes	<b>HRG 5.</b> This option concerns either a pronounced curvature of the femur in the frontal or sagittal plane (1) or curvature that is less pronounced, although the latter is always associated with another obstacle. In an ideal scenario, this obstacle is limited to stage 2 defects; however, it can also be stage 3 osteoporosis and/or difficulties in removing the cement.
			No	
	2 – Good	Stage 3	Yes	<b>Attention</b> In this situation, the femoral isthmus can be used, if this is not already the case (advanced osteoporosis ++ or bone destruction ++) see option 6.  (1) If the femur is straight in the frontal plane, a curvature in the sagittal plane has to be considered, and only if the curvature is pronounced (overall curvature).
			No	
	3 – Mediocre	Stage 4	Yes	
			No	
Femur straight or curved	Isthmus area destroyed (fracture or defects ++) or stage 4 osteoporosis	Stages 1 to 4	Yes or No	<b>HRG 6.</b> Particular situation characterised either by an advanced osteoporosis (stage 4) with very thin cortex and large cylindrical medullary canal, or by a destroyed femoral isthmus caused by a stem fracture or by a long stem loosening.



## Strategy options

Femoral approach(es)	Area(s) of primary stability
<p><b>Option 1 (primary)</b> 1 priority choice and 1 possible choice</p> <ul style="list-style-type: none"> <li>– <b>Endofemoral approach.</b> This is the most common option. Requires a wide lateral and posterior opening of the greater trochanter.</li> <li>– <b>Trochanterotomy</b> if the greater trochanter has become fragile (granulomas +) or if it is an obstacle (coxa vara or history of osteotomy), or if the hip is stiff and/or the prostheses is driven in (perform digastric trochanterotomy). In case of abundant distal cement: a femoral window, or less often, a femoral flap may be indicated (in this case see option 3).</li> </ul>	<p><b>Proximal stability</b> in the metaphyseal-diaphyseal area, while adding bone tissue in the medullary canal, as required. This is the most common option in the case of osteoporosis in an early stage (stage 3).</p> <p>As a general rule, a shorter stem (120 or 140mm long distal component) should be chosen.</p> <p>In case of precarious proximal stability, additional diaphyseal stability can be sought by using a 140mm long distal component to perform a more or less global fixation.</p>
<p><b>Option 2 (intermediary)</b> Two possible choices, depending on whether there are difficulties in removing the cement</p> <ul style="list-style-type: none"> <li>– <b>Endofemoral approach or trochanterotomy:</b> if no difficulties in removing the cement. The fixation area depends on the extent of the defects: proximal stability if defects are minor (option to use in case of stage 3 osteoporosis), or short diaphyseal fixation if defects are greater (See option 1).</li> <li>– <b>Femoral flap:</b> if there are difficulties in removing the cement; always opt for short diaphyseal stability (See option 3).</li> </ul> <p>If there is a cement plug and proximal stability is possible, an endofemoral approach + window can be used, if extent defects in area(s) 2 and/or 6 is minor, particularly in the case of stage 3 osteoporosis.</p>	
<p><b>Option 3 (primary)</b> 1 priority choice and 1 possible choice (1)</p> <ul style="list-style-type: none"> <li>– <b>Femoral flap,</b> the most common choice to remove the cement, perform curettage on geodes and avoid an aggravation of the bone lesions. It is a semicircular lateral flap; generally it is not necessary to combine it with a osteotomy of the medial cortex as the femur is straight in the frontal plane and slightly curved in the sagittal plane.</li> <li>– <b>Endofemoral approach,</b> possible option if there are stage 3 defects and if the lateral or medial cortex has not become too fragile in area 3 or 5. This option should be used in case of stage 3 osteoporosis to aim for a proximal fixation and avoid a purely diaphyseal fixation. In this situation, it is usually necessary to add bone tissue in the medullary canal (See option 1).</li> </ul> <p>(1) If a trochanterotomy is discussed or required, it is often preferable to choose the femoral flap option.</p>	<p><b>Femoral flap = diaphyseal stability</b></p> <ul style="list-style-type: none"> <li>– Bone-implant contact of 3cm in the isthmus area is sufficient, especially if the cortex is good and the medullary canal is more or less conical, in which case a short stem should be chosen (140mm long distal component). If the patient is tall, a 200mm long distal component may be necessary.</li> <li>– If the cortex is good upon contact with the implant and is not too fragile, proximal stabilization of the implant can be achieved on the flap. This option is worth considering in stage 3 osteoporosis and can be useful when the diaphyseal press-fit is mediocre or in order to avoid implanting a stem that is too long.</li> </ul>
<p><b>Option 4 (intermediary)</b> Two possible choices, depending on whether there are difficulties in removing the cement.</p> <ul style="list-style-type: none"> <li>– <b>Endofemoral approach or trochanterotomy:</b> if there are no difficulties in removing the cement, and in order to obtain proximal stability, particularly in stage 3 osteoporosis. In this situation, a femoral window is possible, and it is advisable to make a wide lateral and posterior opening in the greater trochanter (See option 1).</li> <li>– <b>Femoral flap.</b> If there are considerable difficulties in removing the cement, a short diaphyseal fixation is preferable (See option 5).</li> </ul>	
<p><b>Option 5 (primary)</b> 1 priority choice and 1 possible choice</p> <ul style="list-style-type: none"> <li>– <b>Femoral flap</b> in any case, as at least 2 obstacles are combined for the placement of a straight press-fit stem and one has to consider a curvature in the frontal plane, even the slightest one. A flap to avoid a varus placement with a three-point contact, facilitate complete removal of cement and curettage of the granulomas and avoid fracture if the cortex is fragile. In the case of pronounced sagittal curvature (femur straight in the frontal plane), first perform a lateral flap, followed by an osteotomy of the medial cortex. In the case of strong varus or pronounced sagittal curvature, combine the lateral flap with an osteotomy of the medial cortex to restore bone-implant contact. This improves stability while improving bone regeneration and secondary osteointegration.</li> <li>– <b>Trochanterotomy,</b> less common option, although possible when proximal fixation is highly desirable (stage 3 osteoporosis, curvature of the femur and stage 1 or 2 defects) (See option 1).</li> </ul>	<p><b>Femoral flap = diaphyseal stability</b></p> <ul style="list-style-type: none"> <li>– Bone-implant contact of 3cm in the isthmus area is sufficient, especially if the cortex is good and the medullary canal more or less conical, in which case a short stem should be chosen (140mm long distal component). If the medullary canal is cylindrical or if the patient is tall, a 200mm long distal component may be necessary.</li> <li>– If the cortex is good upon contact with the implant and is not too fragile, proximal stabilization of the implant can be achieved on the flap. This option is worth considering in stage 3 osteoporosis and can be useful when the diaphyseal press-fit is mediocre or in order to avoid placing a stem that is too long.</li> </ul>
<p><b>Option 6 (particular)</b> In this situation, placement of a press-fit stem may be impossible or contraindicated</p> <ul style="list-style-type: none"> <li>– When the femoral isthmus is destroyed, implantation of a press-fit stem is impossible since this option cannot be applied at 1/3 distal femur. A locked stem may be indicated in this case.</li> <li>– In case of advanced osteoporosis (thin cortex and very wide medullary canal) and if proximal fixation cannot be achieved, the press-fit stem concept should be discussed thoroughly given the risk of stress-shielding, if the aim is to use a diaphyseal press-fit with a long, wide-diameter stem. The Exeter technique is one possible alternative.</li> </ul>	

## Preoperative Planning

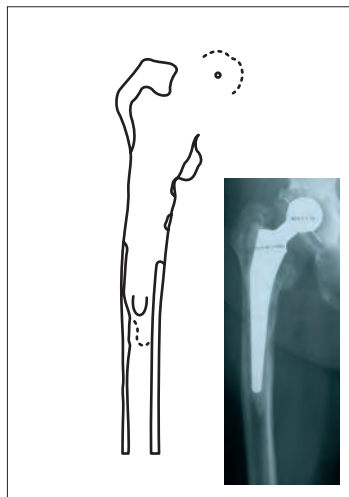
### Making a Preoperative Template

When a flap is indicated, the template may be prepared in the following 5 successive steps:

#### 1. Tracing the Contours of the femur

**Trace the contours of the femur**, highlighting the zones of defects, the distal end of the loosened implant and the cement plug, if any.

**Mark the center of rotation** of the loosened prosthesis.

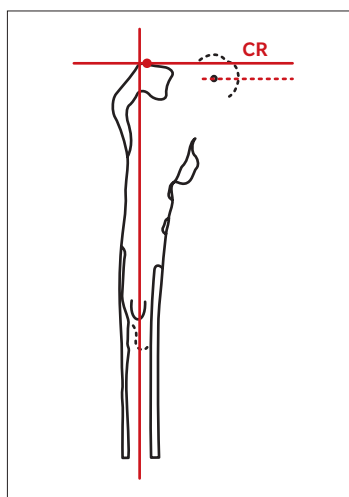


The template should be made on an anterior-posterior X-ray showing the femur over a sufficient length to avoid any off-axis errors (about 15 to 20 cm below the distal tip of the loosened implant).

#### 2. Trace the Axis of the femur

**Centro-medullary axis:** Carefully center the template of a long stem (200 or 260 mm long distal component) in the diaphyseal region, trace the centro-medullary axis and estimate its position at the level of the proximal femur, at the height of the lesser trochanter and in relation to the tip of the greater trochanter.

**Axis of the center of rotation:** Trace a line perpendicular to the centro-medullary axis at the height of the summit of the greater trochanter. In principle, the center of articular rotation of the revision implant should lie on that axis.



This is an important step of the preparation of the template, since it enables to evaluate the extent of a curvature, if any. The curvature is often more apparent on the templates as on X-rays.

**Reminder:** Varus deviations of the femur are frequent in cases of implant loosening.

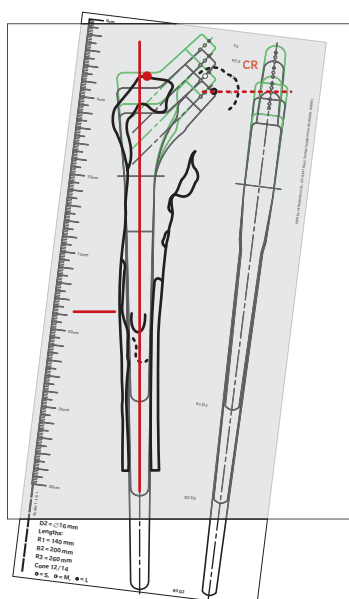
It is now possible to determine any length discrepancy to be corrected. However, it is only an indicative value, as far as during revision surgery, respecting the conventional references to determine the length of the lower limb (degree of subsidence of the prosthesis) is not an absolute rule.

#### 3. Determine the length of the flap

**Position a template on the centro-medullary axis**, so that the summit of the greater trochanter coincides with the center of rotation of the revision stem (choose a medium-sized proximal component with a height of 65 or 75 mm).

**Determine the length of the flap** which has to overcome the obstacles (femoral curvature) and respect the isthmus of the femur at the same time.

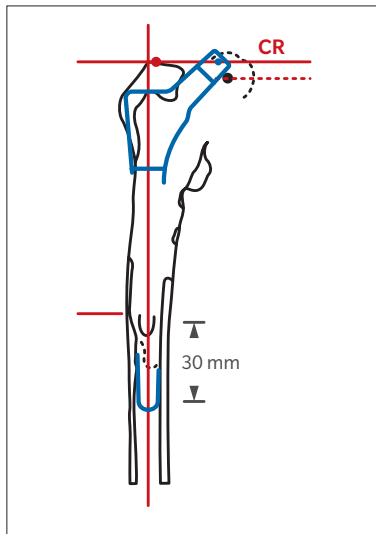
**Trace the distal end of the flap.**



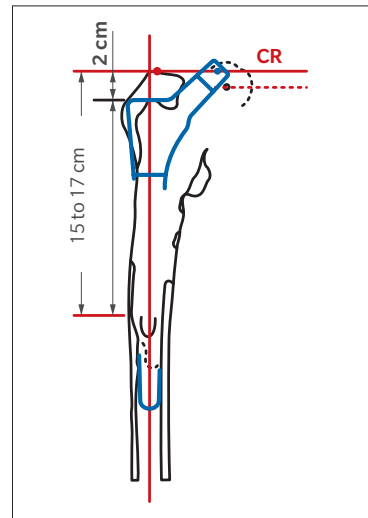
The flap should respect the isthmus of the femur, and its length is usually 15–17 cm.

It is possible to make a shorter flap in the case of dysplastic femur or short patients.





Generally, it is possible to determine the length of the distal component. However, the other references provided by the template (height of the proximal component and diameter of the distal component) are indicative only, and very often the choices made intraoperatively differ from the selected component during the preoperative planning.



This is a particularly important reference point to consider, because during surgery, with the reclined flap, the summit of the greater trochanter can no longer be used as reference to evaluate the depth of penetration of the implant. Only the distal end of the flap can serve as reference to evaluate the position of the revision stem.

The depth of penetration calculated on the basis of the template is indicative only, and the final choice is always made during surgery after completing several trial reductions.

When there is significant shortening, it is often preferable to avoid restoring exact leg length of the two lower limbs.

## 4. Choose the implant length

**This involves determining the height of the bone-implant contact area.** Whenever possible, a short distal component (140 mm) should be selected, preferably with a bone-implant contact over a length of approximately 30 mm.

Trace the contours of the proximal component (in particular the shoulder of the implant and the center of rotation) as well as the distal end of the possible distal component.

## 5. Verify the length of the flap and the depth of penetration of the implant

**Determining the length of the flap** requires to measure the distance between the summit of the greater trochanter and the distal end of the flap.

**The depth of penetration** of the stem is calculated, starting from the distal end of the flap, considering the shoulder of the implant in situ as reference. Since the distance between the center of rotation

and the shoulder of the implant in situ is about 20 mm and the length of the flap is known, it is possible to determine whether the implant is in the correct position or not. The distance between the shoulder of the revision stem and the distal end of the flap must be equal to the length of the flap – 20 mm.

The distance between the center of rotation and the shoulder of the implant is only 10 mm in the proximal component of height 55 mm.

## Conclusions

Making a template is simple if the necessary documentation is available, in particular an X-ray on the frontal plane with sufficient length of the femur. Very often it enables identification of a slight frontal curvature that might otherwise easily remain unnoticed until the centromedullary axis has been traced. Lastly, the length of the flap is the dimension that the surgeon must always keep in mind during surgery, and the final size of the implant is always determined intraoperatively.

## Surgical Technique

### General Consideration

- **Prudence and perseverance are essential while gaining experience.** Any surgeon using a new implant will inevitably require a learning phase, regardless of the prosthesis that is selected. This is a good reason not to change the concept too often.
- **Any concept implies its own specific surgical technique.** The surgeon must familiarize himself with the imperatives of a concept before putting it into practice.
- **A technical error often results in immediate failure.** When the use of a cementless implant has been decided, the surgical technique has to be followed rigorously.
- **The 2 main aims to be achieved are sparing the existing bone stock and ensuring perfect primary stability of the implant.** Sparing the existing bone stock depends, first and foremost, on the choice of the approach to the femur, and it is advisable to avoid changing the strategy during the course of the surgery. To ensure primary stability through the press-fit concept, it is always advisable to comply with the principles defined by **Morscher**, that is, to obtain bone-implant contact as a surface and to ensure that the prosthesis is wedged firmly into place without making the femur too stiff.

The surgical technique will vary depending on the selected approach to the femur: a femoral flap (option 1) or the endofemoral approach (option 2). Before describing these two techniques, however, a few general comments should be made. These considerations are: **rational use of the various implants and practical application of the press-fit concept, or how to prepare a bone-implant contact surface and ensure that the prosthesis is wedged properly into place.**

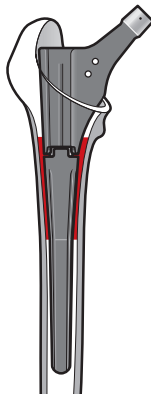
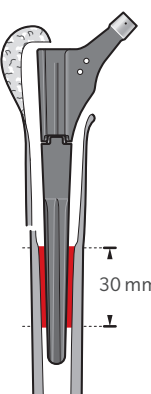
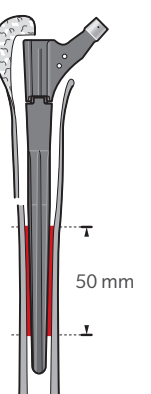
The two surgical techniques are presented in such a way that they can be used separately, which explains certain repetitions.

## Surgical Technique

### Rational Use of Implants

Three rules:

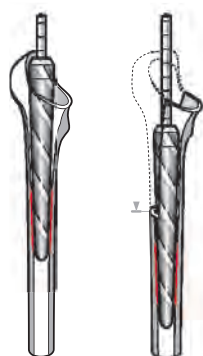
- Increase the diameter of the distal component to decrease the height of the proximal component.
- Give preference to proximal spout components and, where possible, avoid heights of 95 or 105 mm.
- The 260 mm distal component is very rarely used.

Length of the distal component	Height of the proximal component	Total Length	
120 mm	55-175 mm	<b>Endofemoral approach and fixation in the metaphyseal-diaphyseal region</b>	
	65-185 mm	In this case, the “working” part of the distal component is the proximal conical area (height 45 mm). A proximal spout component should be used.	
	75-195 mm		
	85-205 mm		
	95-215 mm	It is frequently preferable to choose a distal component with a length of 140 mm and a greater diameter, with a shorter proximal component.	
	105-225 mm		
140 mm	55-195 mm	Short diaphyseal fixation by the endofemoral approach or after a femoral flap	
	65-205 mm	In this case, the “working” part of the distal component is the distal conical area (height 100 mm). Choose a “spout” or “cylindrical” proximal component.	
	75-215 mm		
	85-225 mm	This implant can also be used for a proximal fixation through an endofemoral approach, in particular when a femoral window must be bridged.	
	95-235 mm		
	105-245 mm	Avoid, if possible, and prefer a 200 mm distal component.	
200 mm	55-255 mm	<b>Long diaphyseal fixation with femoral flap</b>	
	65-265 mm	In this case, the “working” part of the distal component is the conical area (120 mm high), remembering that the 200 mm components always have an intermediate cylindrical area that is not adapted for wedging. If a high component is necessary, chose a proximal component of the spout or “cylindrical” type.	
	75-275 mm		
	85-285 mm		
	95-295 mm		
	105-305 mm		
Reminder: The 260 mm distal components are used very rarely, and mostly for treating complications with multiple bone lesions. In these cases, they are used as a medullary nail.			

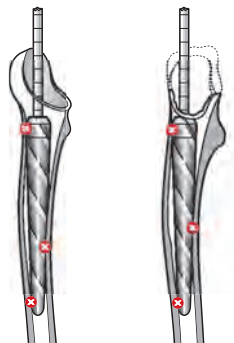
## Surgical Technique

### Preparing a Bone-Implant Contact Surface

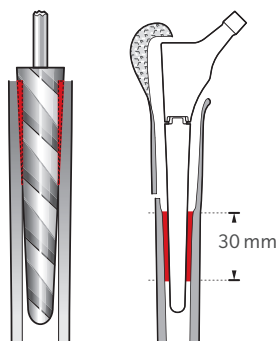
To obtain a bone-implant surface contact is the major objective to achieve when the choice of a press-fit concept was made to ensure the primary stability of an uncemented implant. This preparation performed with reamers or rasps depends on the area of the femur where the primary stability will take place.



It is difficult to prepare a contact surface remaining at a certain distance from this area. Attempting to ream a femur in the isthmus through the endofemoral approach is often risky!



The reamers are not able to make a femur straight if it is curved!



Warning! The references provided by the reamer (diameter and length) are only indicative for the choice of the definitive implant, which must always be done with a test prosthesis.

### Preparation of the femur with the reamers

If diaphyseal fixation is required, the femur is prepared with the reamers, which have the role of giving the medullary canal a conical shape. To obtain bone-implant contact as a surface with the reamers, three rules have to be complied with:

#### Stay close to the fixation area

If the press-fit area can be in the proximal diaphyseal area, preparation through the endofemoral approach is possible.

If the press-fit area has to be in the isthmus of the femur, it is often preferable to carry out a femoral flap.

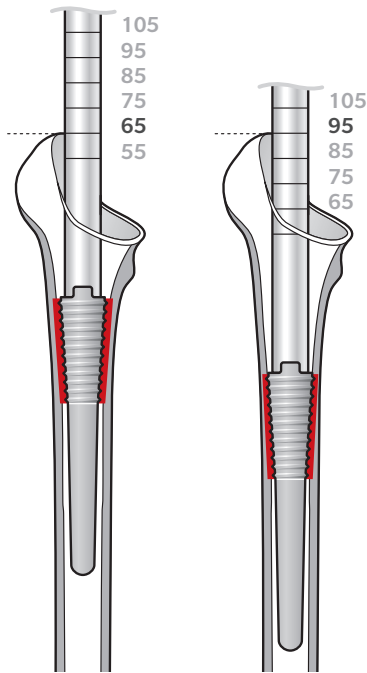
#### Ream a straight segment of the femur

The only role of the reamers is to give the medullary canal a conical shape, and they are only effective if there is a certainty of working on a straight segment of the femur.

#### Ream a short segment of the femur

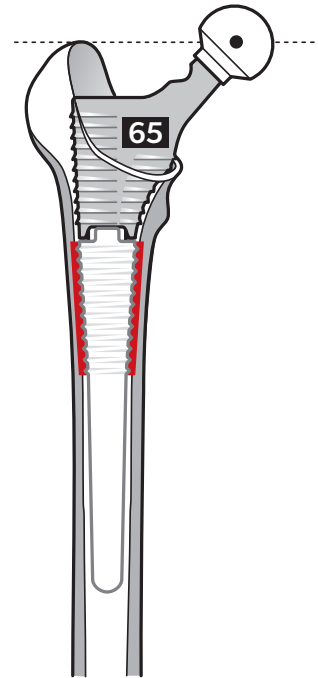
It is easier to make a segment of the femur “conical” if the height of this area is not too large. The surgeon should keep in mind that a medullary canal cannot be made conical over a height of 60 to 80 mm.





In revision procedures, the position of the area of primary stability is always difficult to determine beforehand. A modular rasp enables a selective preparation of the bone-implant contact surface.

The distal parts with a length of 200 mm must not be used in this case.



For this stage of surgery, it is preferable to use proximal spout rasps of a height of 55 to 85 cm.

An assembled rasp can remain stuck in the higher metaphyseal area. In this case, there is no longer a surface contact but only local point contacts, which are often insufficient to guarantee the primary stability

## Preparing the femur with the rasps

It is only possible to prepare a bone-implant contact surface with the rasps if an endofemoral approach is chosen and the primary stability area is situated in the metaphyseal-diaphyseal area of the femur (in revision procedures it is rarely possible to achieve fixation in the metaphyseal area). In this case, take advantage of the modularity of the rasp to perform a two-stage preparation of the medullary canal.

### Preparation of the metaphyseal-diaphyseal area (bone-implant contact area)

- During the first phase, the zone of primary stability has to be “found” by using the distal part of the rasp. This is driven in with the aid of a rasp adapter that has length markings which can be used to select the length of the proximal component for use in the second phase.
- As a preference, a distal rasp with a length of 120 mm is used. But it is also possible to use distal rasps with a length of 140 mm: diameters 14 to 18 mm.

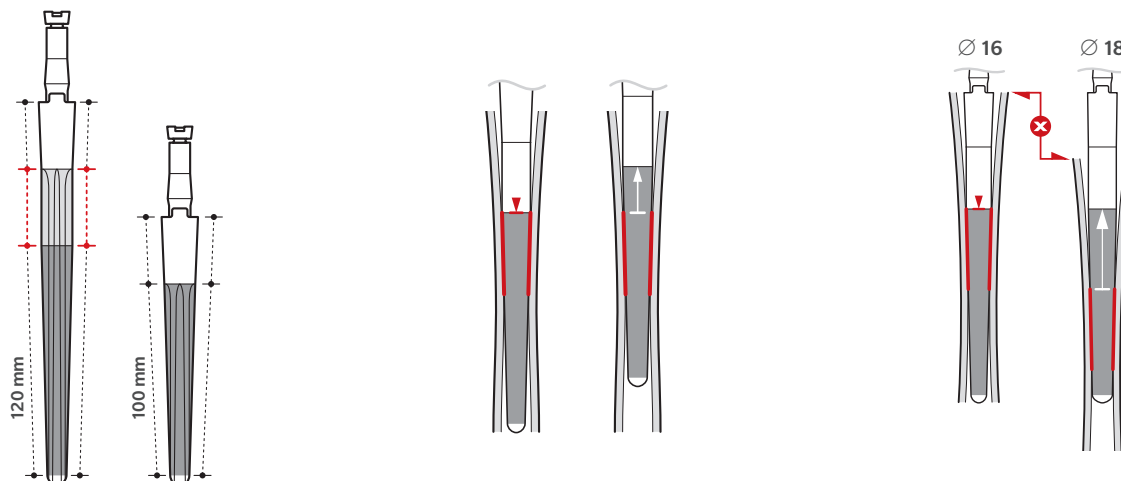
### Preparation of the metaphyseal area (selection of the implant)

- Assemble the two components of the rasp: the distal part used in the first stage with the proximal part whose sizes have been determined in the previous stage.
- Impact the assembled rasp, and when its depth of penetration corresponds to the one achieved in the first stage, a perfect bone-implant contact in the metaphyseal-diaphyseal area is guaranteed.

## Surgical Technique

### Ensuring Effective Implant Fixation

This is a delicate phase of the surgery. In addition to the necessity of an exact perception of the area where the implant will be wedged into place, it is necessary to comply with three rules in order to ensure good fixation.



This feature, which is common to all conical stems, means that a long stem has always a cylindrical area that is not suitable for the wedging of the stem. Contrarily, short stems (diameter 14 to 18 mm) are conical over the whole length, which is a good reason to prefer this type of implant each time it is possible.

Reminder: For the stem of length 120 mm, only the proximal conical area of a height of about 45 mm will serve to wedge the implant into place.

The notion of a reserve of the conical anchorage area must be considered when the preparation of the femur is done with the reamers (diaphyseal fixation). It is difficult to know if there is a reserve of the conical anchorage area or not, if there is no precise knowledge of the area of the femur where the wedging takes place. This is a good reason for the realization of a femoral flap as soon as the fixation is intended to be in the isthmus of the femur.

If a monobloc stem has been selected, the consequence of this choice can be, however, a lengthening of the leg, and this might cause a difference in length between the 2 lower limbs.

A modular system offers a real advantage to overcome that drawback.

### Use the conical part of the implant

For stems of the same length the conical area is situated distally with a constant height. The height of the conical area is 120 mm for a 200 mm distal component and about 100 mm for a 140 mm distal component.

It is important to emphasize that for the distal parts of length 140 mm and diameter 14 to 18 mm, the distal conical zone is lengthened by a proximal, also conical zone (9° taper). This means that these implants are conical over their entire length. This characteristic does not apply to stems with a length of 140 mm and a diameter of 20 mm and more, as the diameter of the distal conical zone is greater than that of the proximal conical zone.

### Keep some conical anchorage area in reserve

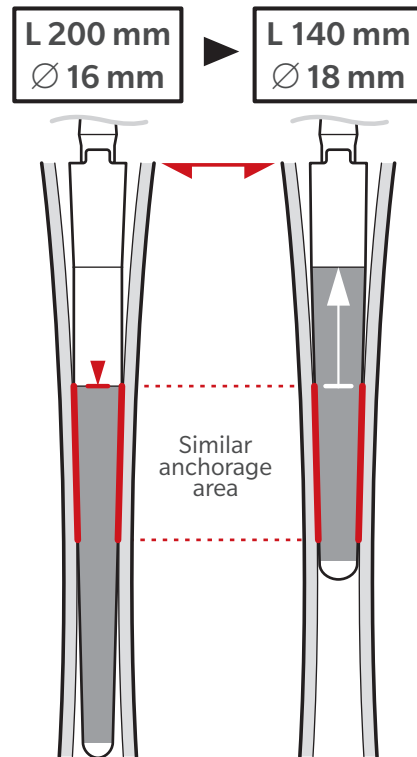
Keeping some reserve of the conical anchorage area means ensuring that the implant is wedged into place (bone-implant contact) with the distal or medium part of the conical area of the implant.

#### Why should part of the conical anchorage zone be kept in reserve?

Moreover, if a stem of 200 mm length is chosen and if wedging is guaranteed through the proximal zone of the conical area, there is a risk of instability in case of even the slightest secondary subsidence, since this will occur in a cylindrical zone that is little suited to wedging.

#### How can some conical anchorage area be kept in reserve if this has not been achieved?

To keep some reserve of the conical anchorage area, it is necessary to increase the diameter of the implant without increasing the diameter of the medullary canal.



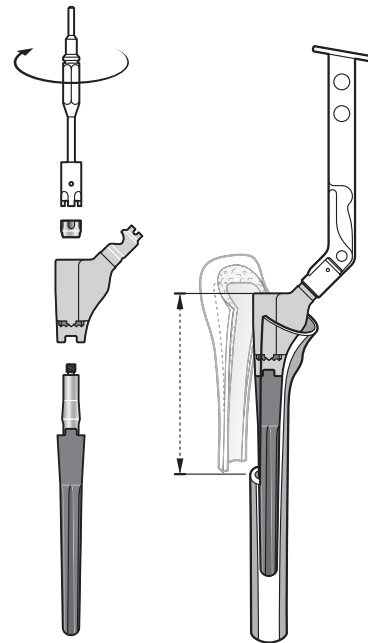
The size of the definitive implant must not be determined with the reamers but with the test prostheses. Furthermore, to choose a stem providing some reserve of the conical anchorage area without risking a leg length inequality, the test prosthesis must also be modular.

A modular system makes the choice of a shorter stem easier, which is always preferable.

## Modularity and reserve of the conical anchorage zone

With a modular system it is easy to increase the diameter of an implant without inducing a difference in length of the 2 lower limbs. The surgeon has two options:

- If a short stem is selected (length 140 mm), increase its diameter and adjust the length of the lower limb using one of the proximal components with different height.
- If a longer stem is selected (length 200 mm), replace it in most cases with a stem of a larger diameter (+2 mm) and shorter in length (length 140 mm). These 2 implants have then **a similar anchorage area**, which lies distally for the short stem, thus providing some reserve of the conical anchorage area, and since the distal component is shorter, the equal length of both lower limbs is conserved or easily adjusted with one of the proximal components.



## Completing an implant placement in two stages

The test prosthesis and the definitive implant do not always wedge into place at the same height!

Implanting the prosthesis in two stages using a proximal trial part makes it possible to choose then the height of the proximal component after having placed the definitive distal component.

## Summary

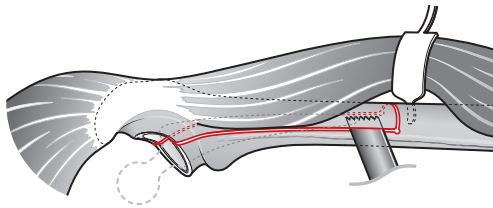
Good wedging ensures at the same time primary stability of the implant. Effective press-fit anchorage does not depend on the extent of the interface bone/implant but on the quality of the wedging.

This stage of the operation is difficult to achieve if, when choosing the implant and implanting the final stem, there is no modular system available.

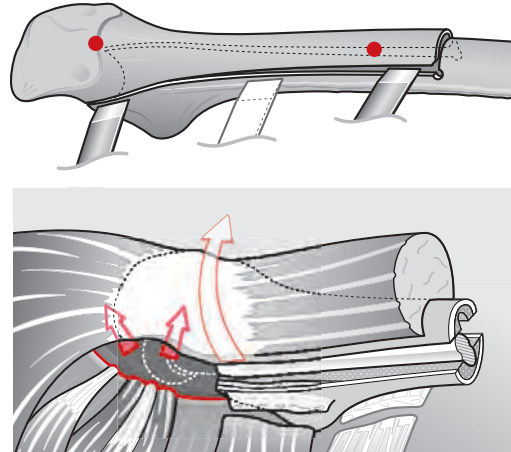
## Surgical Technique

### Option 1: Femoral Flap

During revision surgery, carrying out a femorotomy with a femoral flap is a good way to avoid incidents during the surgery and to ensure a perfect primary stability, which, in this case, is always in the diaphyseal region.



This is an attractive technique; however, it is preferable to avoid it if the hip has become very stiff and the cortical bone is fragile (risk of a fracture during luxation).



An incomplete anterior osteotomy is often the source of difficulties when lifting the flap.

In this case, and after freeing the articular cavity, it is possible to lever and tilt the flap to proceed with the anterior cut, which is usually put in the right "place" if the anterior osteotomy has been properly initiated at both ends.

## Main Objectives

**Both of the two articular approaches, anterolateral or posterolateral,** may be completed. However; it is suggested to prefer the posterolateral access route if a lateral flap is planned.

**In all cases, carry out a pedunculated femoral flap** with the vastus lateralis muscle, combined if necessary with an osteotomy of the medial cortex during the course or at the end of the surgery.

**When selecting the prosthesis,** take full advantage of the modularity of the test prosthesis and, whenever it is possible, place a short stem with a bone-implant contact over a height of approximately 3 cm.

**The definitive implant is placed in two stages.** Assembly of the proximal component is carried out in situ, after having placed the definitive distal component.

## Resecting the femoral flap

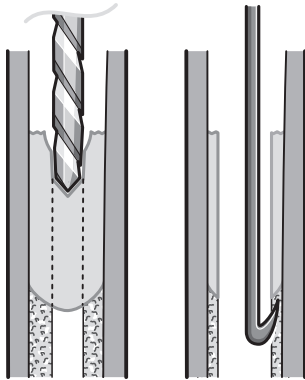
Cut a pedunculated femoral flap of an average length of 15 to 17 cm. To preserve the isthmus area of the femur where primary stability should be achieved,

avoid cutting a too narrow flap in the diaphyseal area or a too long flap with the only objective to remove a cement plug. The femoral flap can be carried out in two different ways:

**After having luxated the prosthesis and removed the implant.** Carry out osteotomies of the cortical bone using the oscillating saw, from the lateral cortex towards the medial cortex, through the medullary canal, after having cut the distal end of the flap.

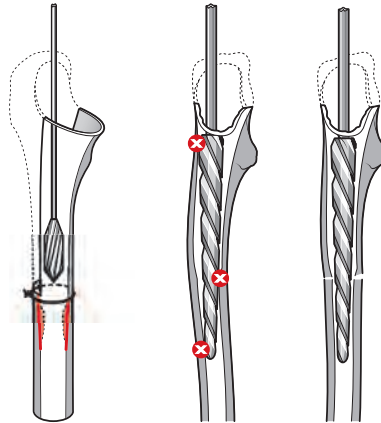
**Prostheses not luxated and implant in place.** The posterior and distal cuts of the osteotomy will be carried out with the oscillating saw and the anterior part with a bone chisel, guided underneath the M. vastus lateralis.

Before making any attempt to lift the flap, it is necessary to free it from its attachment points: cement in the distal and proximal areas (greater trochanter), incomplete osteotomies (anterior or angled distal cut), adhesions at the level of the articular cavity (inner surface of the glutei muscle).



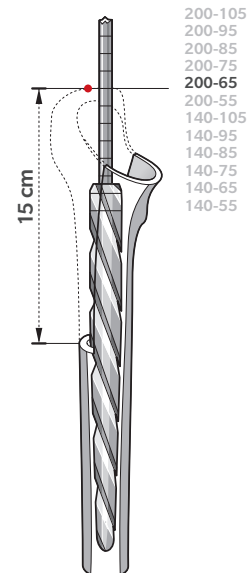
Before removing the cement, ensure a perfect exteriorization of the proximal femur, freeing it from its fibrous and capsular attachments.

Remove the cement plug after removing all the proximally and intermediately lying cement.



There is no necessity in attempting to increase the diameter of the medullary canal unless it is narrow (reaming to 12 or 13 mm is the minimum required).

If the anterior cortical bone is an obstacle, it is preferable at this stage of the surgery to carry out an osteotomy of the medial cortical bone, particularly if it is fragile.



To calculate the depth of penetration with the help of a sterile ruler, the summit of the greater trochanter is positioned at a distance corresponding to the length of the flap from the distal end of the flap.

Avoid being in a situation where a 260 mm distal component is necessary (tip of the greater trochanter in sector 3). In this case, increase the diameter of the reamers to end up within the sector 2, corresponding to a 200 mm distal component or, preferably, within sector 1, which corresponds to a 140 mm distal component.

Remember that the references provided by the reamers are simply indicative for the determination of the definitive implant.

## Removing a cement plug

In a first step, drill a hole in the plug with the 6 mm drill bit, after making sure that the latter is correctly centered.

In a second step, after having verified that there is no malpositioning, enlarge the opening to about 11 mm, so as to pass a wide cement extraction curette through it.

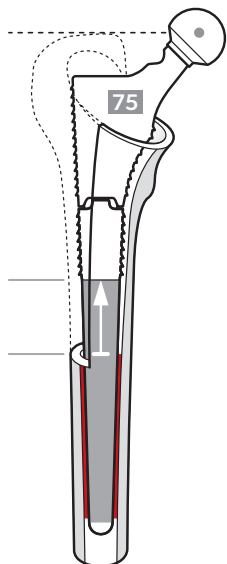
## Calibrate the femur and verify the lateral axis

- In a first step, use the cylindrical reamers to eliminate any narrowing at the end of the prosthesis and calibrate the medullary canal.
- In a second step, verify whether the sagittal curvature (anterior cortical bone) is an obstacle preventing progress of the reamer along the axis of the diaphysis. To do this, use a long conical reamer with a diameter smaller than the inside diameter of the medullary canal.

## Reaming the femur (making the medullary canal conical)

Increase the diameter of the reamers progressively and evaluate the depth of penetration by aligning the mark on the handle with the line passing from the summit of the greater trochanter to the center of rotation of the implant.

**Example opposite:** For a 15 cm long flap the summit of the greater trochanter will correspond to the mark 200–65. This reference corresponds to an implant of the same diameter as the reamer in place and 265 mm long, i.e. a 200 mm long distal component (the digit 200) coupled with a **65 mm** high proximal component.



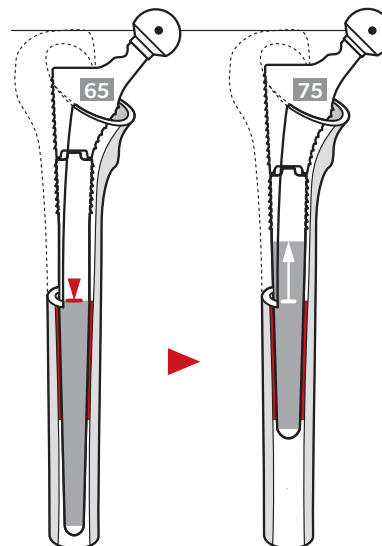
If the endofemoral access route has been selected, it is very difficult, if not impossible, to evaluate and compare the position of the conical area of the implant with the anchoring area in the femur, if the latter is in the isthmus.

The need to evaluate and compare the position of the conical area of the implant is a good reason for not making a flap too short!

## Selecting the distal component

**Warning:** In practice, the distal component (which ensures primary stability) and the height of the proximal component (which restores the length of the lower limb) are selected simultaneously during the course of the surgery. However, in order to clarify the explanations, these two stages of the surgery will be described separately below.

Assemble the two parts of the test prosthesis corresponding to the references provided by the reamer and impact them gently into place by applying light hammer blows. This is to avoid impacting it further by force and thus running the risk of enclosure. After impacting them, evaluate and compare the position of the conical area of the implant with the anchoring area (bone-implant contact area). The surgeon may be confronted with the following two situations:



**Reminder:** To restore some reserve of the conical anchorage area, it is necessary to increase the diameter of the implant without increasing the diameter of the medullary canal.

Replacing a 200 mm stem (with no reserve of conical anchorage area) with a shorter, larger-diameter stem is a situation that the surgeon will be confronted with occasionally (these two implants have a similar anchoring area).

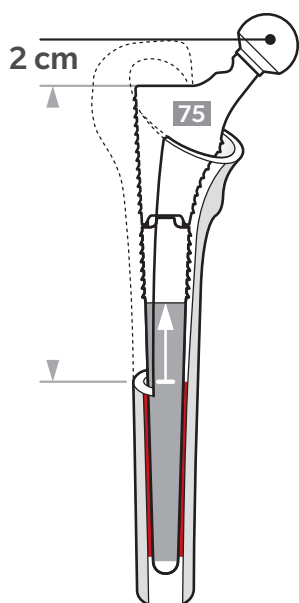
### There is some reserve of the conical anchorage area

In this case, primary stability is ensured with the distal part of the conical area of the implant. The proximal line limiting the working conical area of the stem in place is situated clearly (4 to 5 cm) above the distal end of the flap.

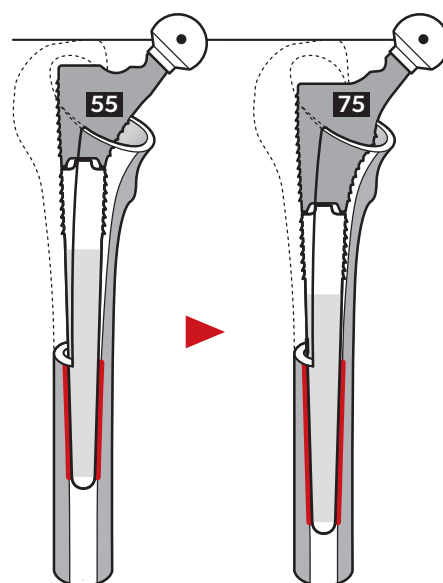
### There is no reserve of the conical anchorage area

In this case, primary stability is ensured by the proximal part of the conical area. The proximal line limiting the working conical area of the stem is situated at the height of or below the distal end of the flap.

- If the distal component is 200 mm long, it will be necessary to replace it with a 140 mm distal component with a larger diameter of +2 mm, usually without additional reaming.
- If the distal component is 140 mm long, all that has to be done is to increase the diameter of the implant. In this case, additional reaming may be necessary.



This situation may occur when the hip is still sufficiently lissom and when the shortening of the lower limb is not particularly significant.



If a 140 mm long distal component has been selected, it is possible to decrease its diameter without running into any risks, since this implant has a conical proximal area that can take over the function of the distal conical area in the event of significant subsidence.

The same cannot be said of the 200 mm long distal components, as these have a cylindrical intermediate area that is not suited for the wedging effect.

## Selecting the proximal component

At this stage of the surgery it is necessary to choose a proximal component of **medium height** (65 or 75 mm) to have some reserve when placing the definitive stem. Whenever possible, a proximal component with a height of 95 or 105 mm should be avoided.

**Warning:** During revision procedures, respecting the usual reference points (summit of the greater trochanter – center of rotation with a ball head, neck size M) in order to calculate the correct length of the lower limb is not an absolute rule. It is always advisable to carry out several trials before making the final choice. The surgeon may be confronted with any of the three following situations:

### The correct choice has been made

The length of the lower limb has been restored using one of the average-sized proximal components (65 or 75 mm) and the reduction can be carried out without any difficulty.

To calculate the depth of penetration, measure the distance between the shoulder of the test prosthesis and the distal end of the flap. This distance corresponds to the length of the flap – 2 cm.

### Low proximal component (55 mm)

It will be necessary to choose a higher proximal component (65 or 75 mm).

– In most cases, additional reaming will be carried out in order to increase the depth of penetration of the distal component, which can relatively easily be achieved if there is a sufficient reserve of the conical anchorage area.

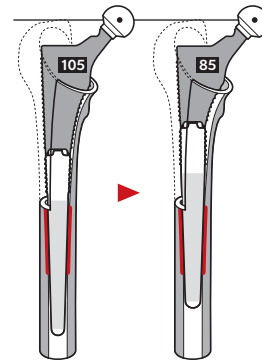
– If it is also necessary to increase the height of the proximal component and simultaneously decrease the length of the lower limb in relation to the usual reference points (difficult reduction due to stiffness of the joint), one may decrease the diameter of the distal component.



### High proximal component ( $\geq 85$ mm)

It will be necessary to decrease the degree of penetration of the distal component to be able to use a lower proximal component.

- If the distal component is 140 mm long, the diameter of the distal component must be increased without changing its length.
- If the distal component is 200 mm long, it is frequently preferable to shorten its length while increasing its diameter, if necessary by +4 mm. In this case, additional reaming may be necessary.



## Placing the definitive implant into place in two stages

The definitive implant is placed in two stages using a proximal trial part provided for this purpose and can only be carried out if a femoral flap has been cut.

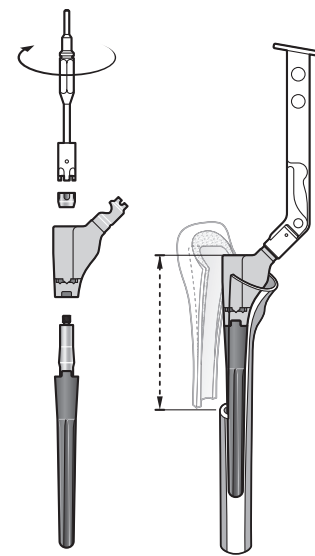
### Distal component

- Inserting a proximal trial implant, the height of which has already been determined in the previous operative step.
- Gently hammer in the definitive distal component and at the same time check the depth of penetration with a ruler. Wait a moment and check again whether penetration of the implant is complete.
- Trial reposition to select the height of the final proximal component and check which orientation it should have (antetorsion).

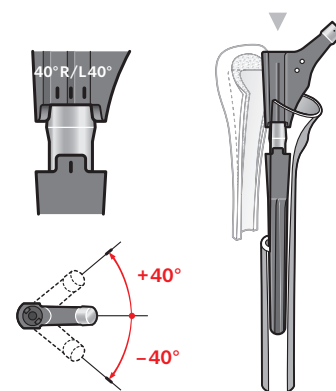
### Proximal component

Rinse carefully the Morse taper, position the proximal component by hand with the required antetorsion.

Tighten the assembly with the torque wrench and screw in the conical nut. Carry out the reduction and select the neck length of the ball head.



Depending on the quality of the cortical bone, a difference in penetration of  $\pm 5$  mm compared to the test prosthesis is frequent (penetration of the fins into osteoporotic cortical bone may cause a difference of 10 mm or more).

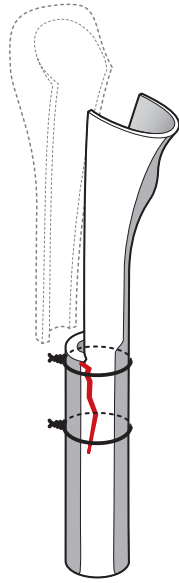


It is recommended to hold the handle of the stem tensioner very firmly while assembling the proximal component.

### Important

When assembling the proximal with the distal implant component, hammering is strictly forbidden. It is necessary to use the assembly technique (see annex 1).

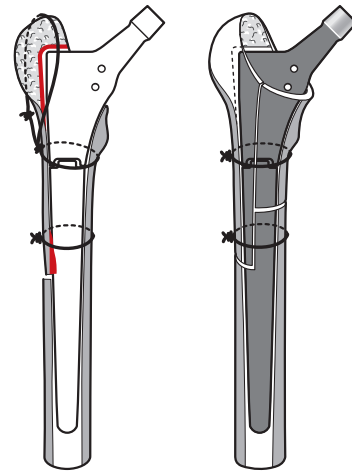




Retrieve the implant from its seat, reduce the crack with one or more cerclages of the femur then proceed by impacting the implant back into place, constantly verifying that the crack is reduced.

Disassemble the proximal component and take a lower component, or remove the implant from its seat and carry out additional reaming.

Remove the implant from its seat, correct its orientation and then wedge it back into place.



When putting the flap back into place, the obstacles preventing a good contact at the level of the osteotomy cuts are often located at the height of the greater trochanter (corticalization of the cancellous bone) and at the distal end of the flap (endomedullary ossification).

#### Important

If the cortical bone is of good quality, properly restoring bone-implant contact and performing good cerclage helps improve an implant's stability. This will facilitate the proximal transmission of stresses.

## Incidents

### Crack in the diaphyseal femur

A crack may happen at the height of one of the two edges of the distal end of the flap if the latter has not been marked by two drilled holes.

### Implant is too high

This may happen if the surgical protocol has not been complied with at the time of selecting the implant.

### Movement of the implant at the time of assembly

This incident happens if the stem tensioner is not held firmly when assembling the proximal component.

## Putting the flap back into place

If the femur is straight in the frontal plane and slightly curved in the sagittal plane, a good preparation of the endomedullary surface of the flap is sufficient to reduce the gaps. If the femur is curved, it is necessary to carry out an osteotomy of the medial cortex in order to restore bone-implant contact.

Osteosynthesis of the flap is completed with two cerclages or more if required. If the greater trochanter has become fragile, use the proximal cerclage to carry out an additional mounting in the form of a lateral and posterior brace.

If the bone defects or gaps in the flap are not very pronounced, they could be ignored. For larger areas, it is recommended to introduce additional bony material in the form of small, autologous corticocancellous grafts.

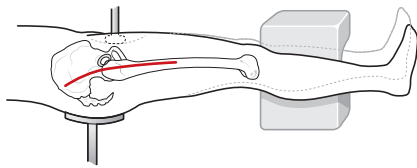
## Surgical Technique

### Option 2: Endofemoral Approach

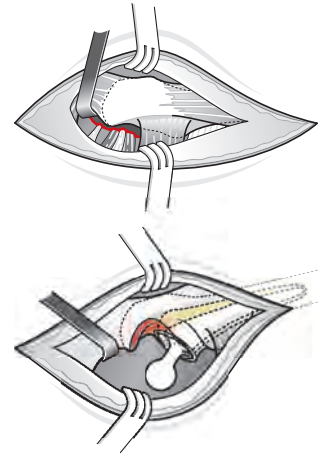
This option should be chosen when:

- the femur is straight in the frontal plane and slightly curved in the sagittal plane
- and if the bone defects are not too significant.

In this situation, the objective is to achieve fixation in the metaphyseal-diaphyseal region or, less frequently and only when required, in the proximal diaphyseal area.



Immobilize the pelvis posteriorly with a sacral support and anteriorly with a pubic support, making sure that the femoral blood vessels are not compressed. Keep the lower limb in an horizontal position with a pad that can be easily removed.



It may be necessary to cut through the crural square and the aponeurotic extension of the M. gluteus maximus.

Before explanting the implant it is often necessary to open the greater trochanter.

### Main objective

**Ensure a good exteriorization of the femur.**

It is not possible to prepare the medullary canal properly if the femur remains attached deep in the articular cavity.

**Open the greater trochanter widely** to be sure of being in the axis of the femoral diaphysis and avoiding placing the implant in a varus position.

**The cement must always be removed completely.** A perfect view of the medullary canal is required for this stage of the surgery, and a femorotomy as a femoral window may be indicated.

**At the time of selecting the implant,** the objective must be to ensure fixation in the metaphyseal-diaphyseal area of the femur. If this is not possible, try to achieve a short diaphyseal fixation. In any case, use a 120 or 140 mm long distal component.

It is not recommended to implant a 200 mm long distal component if the endofemoral approach has been selected.

**The definitive stem is placed in a single stage** after assembling the two components of the prosthesis outside of the femur.

### Articular approaches

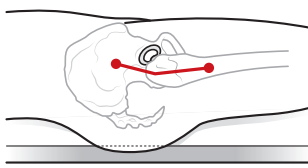
#### Posterolateral approach

Place the patient in the lateral decubitus position.

Make a skin incision centered on the greater trochanter and curved slightly backwards at the level of the pelvis. Make an incision in the fascia lata and the gluteus maximum along the muscular fibres.

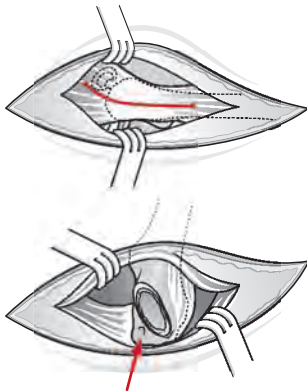
Identify and retract the posterior edge of the M. gluteus medius before carrying out a posterior capsulotomy, resecting the pyramidal, obturator and gemellus tendons at the level of the bone.

Free the proximal femur in order to ensure a perfect exteriorization of the femur.

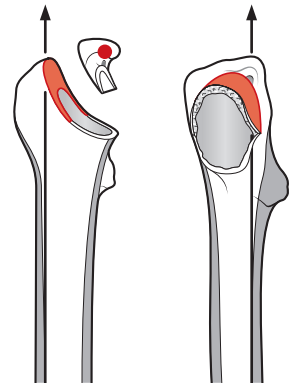


Immobilize the pelvis with a wedge resting against the counter-lateral hip.

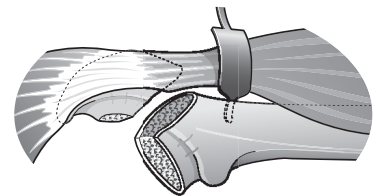
The hip to be operated must protrude slightly from the operating table.



Avoid making the transgluteal incision too far forward to respect the anatomical continuity between the gluteus medius and the vastus lateralis muscles. Remember that the point of penetration of the instruments is at the height of the trochanteric fossa.



Complete the opening of the greater trochanter with the aid of a conical reamer when preparing the medullary canal (see "Preparation of the femur and the correct choice of implant," page 35).



When a trochanterotomy is indicated, it combines both the articular and femoral approach.

### Anterolateral approach

Place the patient in the dorsal decubitus position. Make a skin incision centered on the greater trochanter, slightly angled upwards and forwards at the level of the pelvis.

Transgluteal incision and incision of the vastus lateralis muscle in the digastric area. After removing the prosthesis, free the proximal femur by resecting the pyramidal tendon and the posterior capsule at the level of the bone to ensure good exteriorization of the femur.

## Femoral Approaches

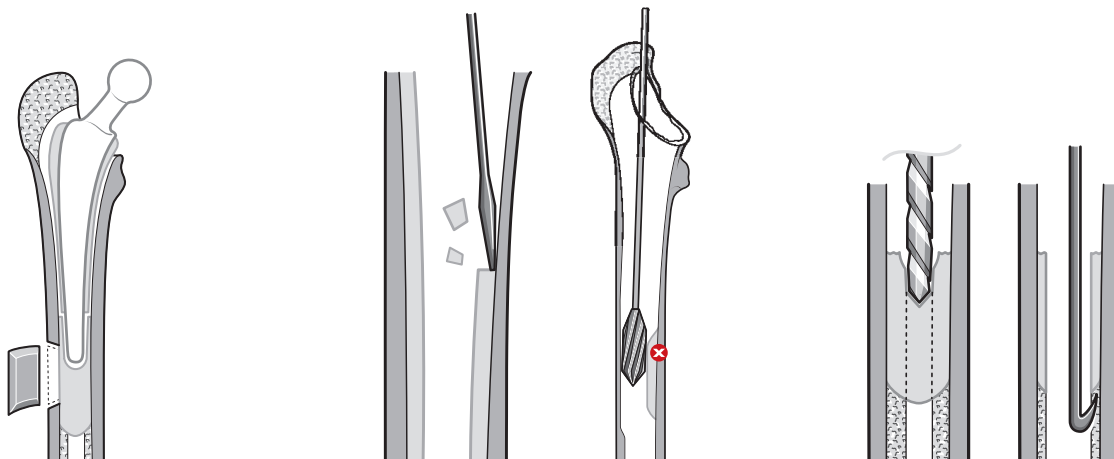
### Opening the greater trochanter

If the endofemoral approach is selected, a wide lateral and posterior opening in the greater trochanter will be necessary.

This stage of the surgery is completed with the aid of the forceps and hollow chisel as the bone is frequently corticalized and sclerotic on this part of the femur.

### Trochanterotomy

It is suggested to carry out a digastric trochanterotomy preserving the insertions of the vastus lateralis.



A femoral window enables good centering of the instruments used to extract a cement plug (see below).

Beware of residual fragments of cement, as these could mislead to off-axis reaming or to a via falsa.

Proceed with the removal of the cement plug after complete excision of the intermediate cement.

If the femoral stem is off axis, beware of following a via falsa.

## Bone-implant contact surface

### Femoral Window

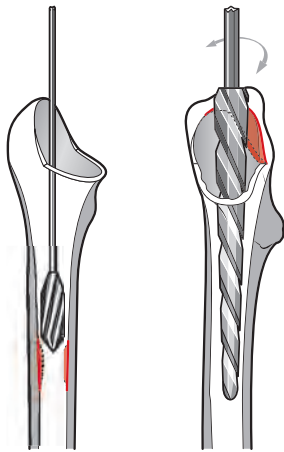
If the endofemoral approach or a trochanterotomy has been selected, a femoral window may be indicated in order to remove a cement plug. The window may be either lateral or anterolateral, and if the cortical bone is thick, it will be made in the form of a wedge, which will make it easier to put it back into place without osteo-synthesis.

**In the intermediate area:** Remove the cement, breaking it piece by piece, carefully controlling the bone-cement interface.

**Cement plug:** Drill a hole in the plug with a 6 mm drill bit, then enlarge the opening, up to 10 or 11 mm, to pass a cement extraction curette through it.

## Removal of the cement

This stage of the surgery is often long and laborious, and even the use of a mechanical cement extractor does not prevent from a via falsa if the femur is curved.



If proximal fixation is required, then calibration of the femur using a cylindrical reamer of at least 12 mm diameter is necessary.

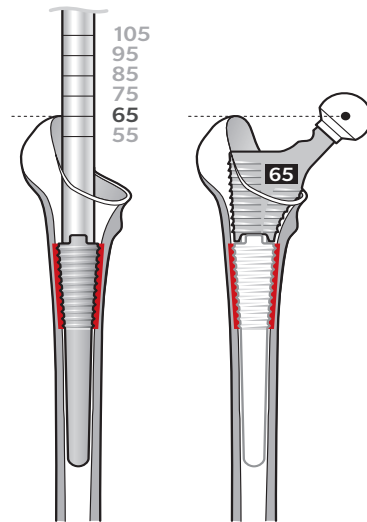
A long conical reamer will enable to verify the alignment of the proximal femur in relation to the diaphyseal femur.

## Preparation of the femur and the correct choice of implant

### Calibrate the femur and adjust the opening of the greater trochanter

Calibrate the femur with a cylindrical reamer and adjust the opening of the greater trochanter with a conical reamer having a diameter smaller than the medullary canal.

Following this first stage of the surgery, aim to achieve fixation in the metaphyseal-diaphyseal area and, if this fixation mode is not possible, try a short diaphyseal fixation.



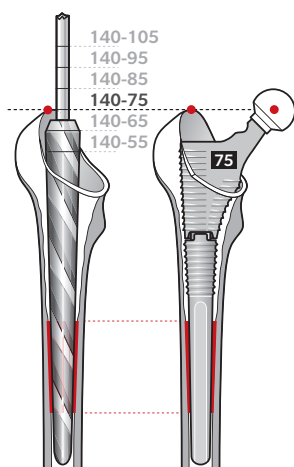
If it is difficult to impact the assembled rasp, then it is possible to perform a separate preparation of the metaphysis with a proximal rasp component without using a distal rasp component.

It is possible to ensure a fixation in the metaphyseal-diaphyseal area with a distal component of length 140 mm, which might be indicated when a femoral window was done in order to remove the cement plug.

### Metaphyseal-diaphyseal fixation

The preparation of the femur is realized with a rasp that will also be used as a test prosthesis. It is suggested to perform a preparation of the femur in two stages.

- In a first stage, impact the distal rasp of length 120 mm or 140 mm (with a diameter of 14 to 18 mm) with the graduated cylindrical handle until a perfect primary stability is achieved. Evaluate its depth of penetration in order to choose the proximal part of the rasp.
- A second step assembles the two rasp components into one piece. In doing so, the depth of penetration must be maintained, which was determined in the first step. If it is not possible to ensure primary stability at this level, opt for a short diaphyseal fixation – see next page.



Example: A 1-75 reference refers to a distal component with the diameter of the reamer and a length of 140 mm (number 1) connected to a proximal component of height 75 mm.

In this situation, the rasp is useful for completing the preparation of the femur while also serving as a prosthesis.

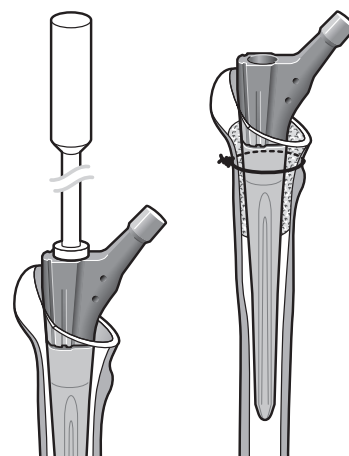
### Short diaphyseal fixation

In this situation, preparation of the femur is done with the reamers. Increase the diameter of the reamer to end up, in any case, within the sector 1, corresponding to a 140 mm distal component which is indicated in this case.

The implant is selected using the rasp according to the references given by the reamer.

### Trial repositioning

During revision procedures, respecting the usual reference points (summit of the greater trochanter – center of rotation with a ball head, neck size M) in order to calculate the correct length of the lower limb is not an absolute rule. It is advisable to carry out several trials before making the final choice and to take full advantage of the modularity (it may be necessary to increase the height of the proximal component). The trial reductions should be carried out using a femoral head with a neck size M in order to keep some flexibility when putting the definitive implant into place.



Do not correct the antetorsion of the implant while impacting it.

Adding bone in the medullary canal enables the control and limitation of the depth of penetration of the prosthesis. Simultaneously, it enhances the stability.

## Placing the definitive prosthesis

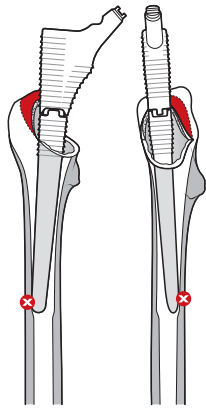
If the endofemoral approach has been selected, the two components of the prosthesis are assembled outside of the femur (see Annex 1).

### Important

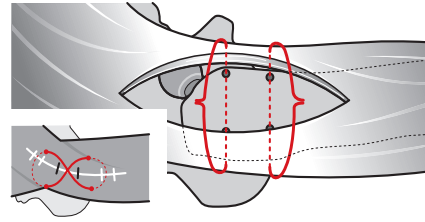
Assembling the proximal with the distal component in situ by the endofemoral approach could lead to the risk of a defective assembly, even when using the hollow reamer designed for adjusting bone obstacles at that level of the femur.

After assembling the two parts of the prosthesis, introduce the implant oriented in the correct antetorsion and screw the impactor on the proximal component.

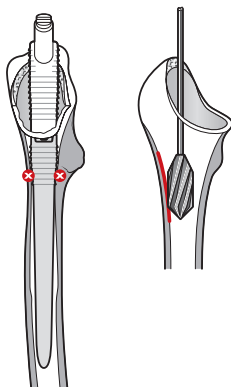
Continue impaction until a cortical sound is obtained. Then wait for a few seconds and verify once again that the implant is set. Carry out the trial reduction and make the final choice of the ball head neck length.



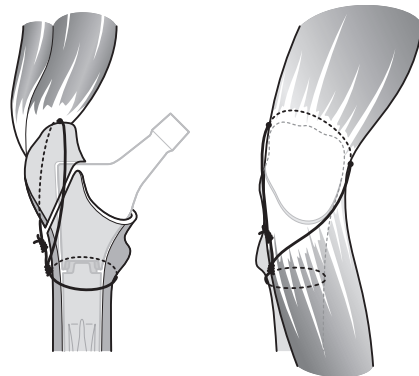
This type of incident occurs frequently if a varus curvature of the femur has not been considered, even if this curvature is not very pronounced.



It is advisable to carry out an additional mounting in the form of a lateral stay from the base of the greater trochanter with a transosseous point.



- In the proximal region, use a cylindrical reamer, diameter 16 to 18 mm, while keeping contact with the lateral cortical bone.
- In the diaphyseal area, increase the inner diameter of the medullary canal to 11 or 12 mm.



If this is a traditional trochanterotomy, create a mounting with 3 metal wires and a lateral stay.

## Incidents

Incidents may occur when preparing the femur and usually consist of difficulties in impacting the rasp.

### Insufficient lateral or posterior opening of the greater trochanter

This leads to an incorrect positioning of the rasp, and any attempt to correct that position or to impact it further by force could lead to a fracture of the greater trochanter or, if this does not happen, to a varus position of the implant.

### Narrow femur in the sagittal plane in the proximal region

This can be an obstacle to the penetration of the rasp or cause excessive antetorsion. An additional reaming is often necessary.

The same applies if the femur is narrow in the diaphyseal region.

## Closure of the joint

Incidents may occur when preparing the femur and usually consist of difficulties in impacting the rasp.

**Anterolateral approach:** Reattach the anterior digastric muscle using 2 transosseous points.

**Posterolateral approach:** Whenever possible, reattach the pelvic-trochanteric and the posterior capsule.

**Digastric trochanterotomy:** Perform a lateral and posterior stay maintained by a cerclage on the proximal femur.

## Postoperative Treatment

As far as the instructions to be given to the patient for the period immediately following the surgery are concerned, it is advisable to keep them both simple and pragmatic. It is possible to distinguish between two different situations:

### Bone-implant contact surface

**The prosthesis is stable**, since it has been wedged perfectly into place in the femur, featuring cortical bone with high mechanical strength and a conically shaped medullary canal.

In this situation, loading is authorized straight away, using two forearm crutches that have a dual role: taking the weight off the hip and avoiding incorrect movements, in the expectation of a complete healing of the soft tissues. Immediate physiotherapy is functional only, and it aims to teach the patient what movements should be avoided in order not to have rotational stresses to the prosthesis, in particular when standing up from a seated position or when going up- or downstairs. The patient will undergo a follow-up examination, including an X-ray control, a couple of months after the surgery. At this time a more active physiotherapy may be prescribed. Use of any aid will be abandoned progressively as a function of the recovery of the muscular strength, with the awareness that, generally speaking, there should be no hurry to cease using the crutches.

**The prosthesis is not judged to be perfectly stable**, since the surgeon has some doubts on the quality of the wedging of the implant. Whatever may be the reasons for this concern, it is recommended to be cautious and not to authorize even partial loading for several weeks. During this period of nonloading, it is preferable to keep the patient under supervision and, if she/he is admitted to a specialized center, order that she/he does not undergo any active physiotherapy throughout this period. At the end of this period, and after a follow-up X-ray, loading may be authorized. In principle this should be gradual; however, it is in practice nearly always complete and immediate.

This cautious attitude is recommended in the early stages of experience with the implant. Moreover, it should be stressed that each patient is a unique case and that the period for which loading should be avoided can vary.

It is the responsibility of the doctor to determine the appropriate postoperative treatments for each patient based on his/her health conditions.

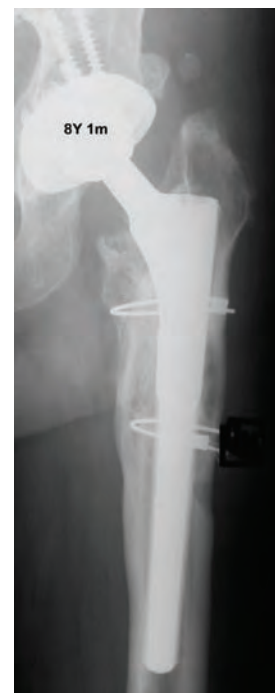
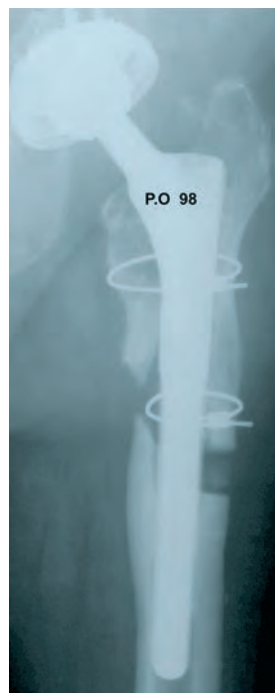
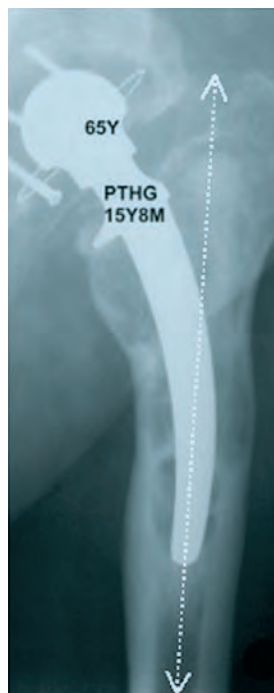

## Case Studies (Femoral Flap)

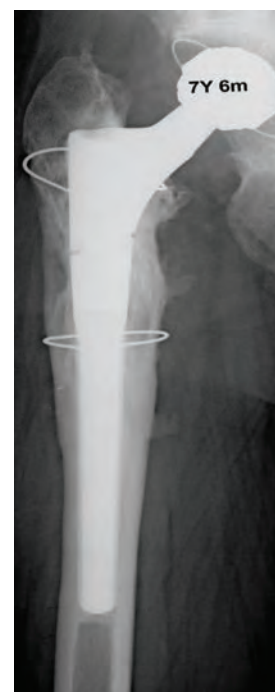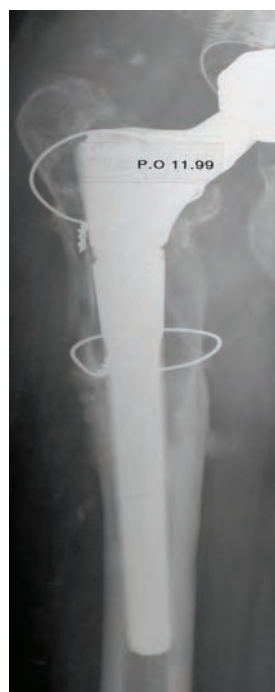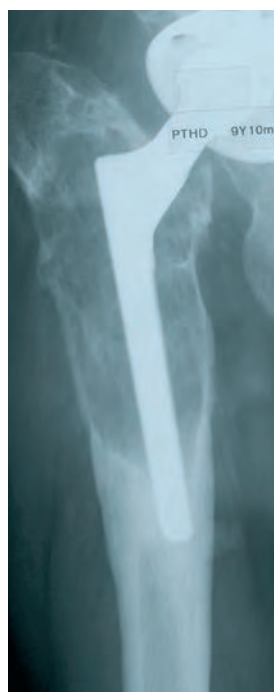
65-year-old male patient, left THP (15 years). Loosening with granulomas+. Corticalized femur (no osteoporosis). Varus deviation of the proximal femur. Lateral flap with pedicle and medial cortical osteotomy, PFM-Revision stem with short diaphyseal fixation and a cementless St. Nabor cup. Flap with gap+ and medial cortical defect.

Results after eight years: very good bone regeneration and perfect osteo-integration, with no stress-shielding.



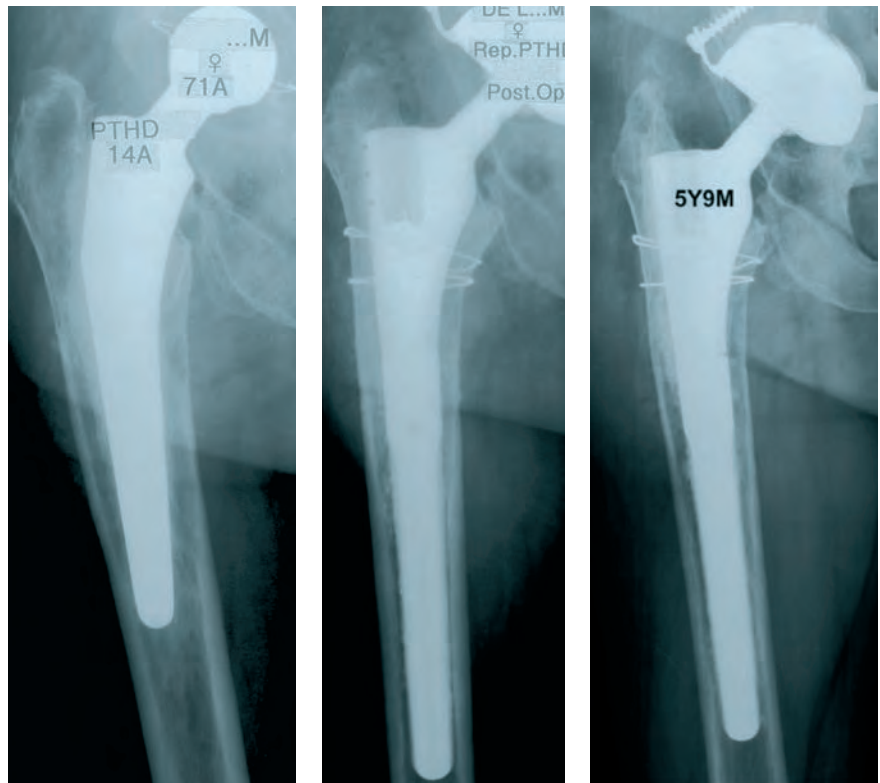
52-year-old male patient. Right cementless THP in 1990 (10 years) on a dysplastic hip. Significant bone destruction due to granulomas. Valgus deformation of the femur (not very frequent). Lateral flap, short diaphyseal fixation, no bone grafts.

Results after 7.6 years: excellent bone regeneration and perfect osteo-integration, with no stress-shielding.

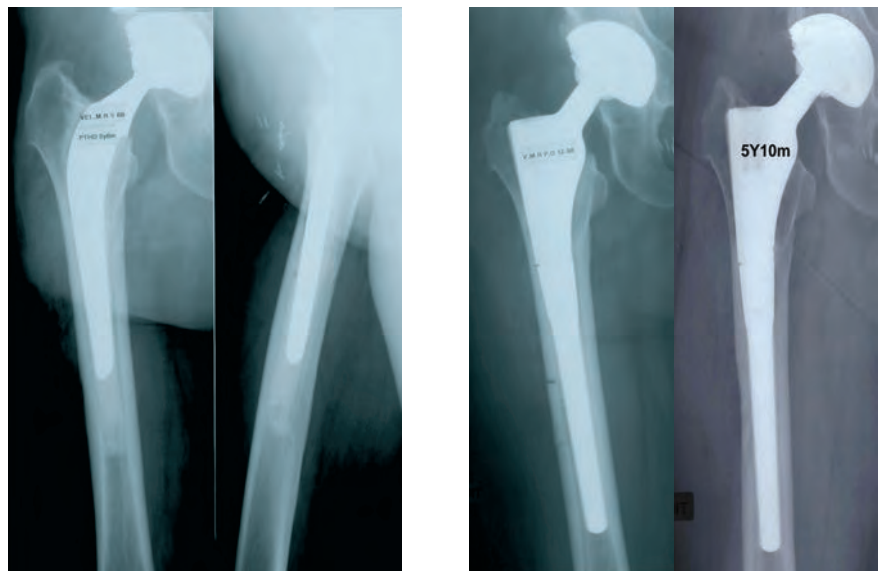


## Case Studies (Endofemoral Approach)

71-year-old female patient, right THP 1982 (14 years). Only slight loosening but with medial cortical granulomas and varus stem. Straight femur and osteoporosis±. Revision via the endofemoral route: proximal fixation with endomedullary bone graft and cerclage of the proximal femur. No diaphyseal fixation. Results after 5 years and 9 months: moderate atrophy of the proximal femur but no significant modification of the cortical bone, good proximal osteointegration.



66-year-old female patient. Right THP, early aseptic loosening. Bone stock retained, femur straight in the frontal plane and slightly curved in the sagittal plane, cement plug. Endofemoral approach and window for removing the distal cement. Fixation in the metaphyseal-diaphyseal area. Results after 23 months: good osteointegration and no modifications of the cortical bone.



## Conclusions

### What to do

- Have suitable X-rays available before the surgery, in order to carry out a radiological analysis enabling the “correct” femoral approach to be selected, considering the imperatives imposed by the press-fit concept.
- Do not hesitate to choose a femoral approach in the form of a pedunculated lateral flap. This is an excellent way to ensure a straightforward revision and an effective press-fit.
- Remove all the cement without damaging the bone lesions further. This requires a perfect view of the endomedullary canal.
- Undertake preparation of the implant area with the rasps or reamers, once there is a certainty of working on a straight segment of the femur and after removing all intramedullary obstacles.
- If an endofemoral approach has been selected, it is necessary to create a large opening in the greater trochanter. Further, diaphyseal fixation will be aimed to only if proximal fixation in the metaphyseal-diaphyseal area is not possible.
  - First of all, it is necessary to prepare the area for receiving the implant using the rasps; if diaphyseal fixation should be necessary, the reamers will have to be used.
  - The selection of the implant, which is done using the rasp that also serves as test prosthesis, is a very important stage of the surgery and entails exploiting the modular nature of the implant properly.
  - The definitive implant will be selected after carrying out one or more trial reductions and it is advisable to keep a safety margin with the modular ball heads by carrying out the trial reductions with a ball head with a neck size M.
  - The definitive stem is implanted in a single stage, after assembling the two components of the prosthesis out of the femur. If the depth of penetration of the definitive prosthesis does not correspond exactly to that of the trial prosthesis, the length of the neck of the ball head can be used to get an offset.
- If a femoral flap has been selected, fixation must necessarily be diaphyseal. In this situation, the reamers are used to give the medullary canal a conical shape and not for the selection of the implant, which will always be done with the test prosthesis.
  - In order to ensure primary stability and to keep some reserve of the conical anchorage area when wedging the implant into place, it is necessary to use the conical area of the implant. To achieve this, it is always advisable to give priority to the implant’s diameter rather than its length, which often implies using a short stem.
  - When choosing the implant with the trial prosthesis, it is advisable to avoid choosing an extreme proximal component (55 or 105 mm) to keep a margin when introducing the definitive implant, which is always carried out in two stages. Proximal components with a height of 95 and 105 mm should be avoided.
- When a femoral flap has been performed, it must be carefully put back in place, especially when the fixation in the diaphyseal region is not too favorable. A cerclage in the form of a lateral stay must be performed when the greater trochanter is fragile.
- During the postoperative treatment, give clear instructions to the patient. If complete loading is not possible or risky, it is preferable to keep the patient under supervision during the period of nonloading.

## Conclusions

### What not to do

- Do not start the surgery without carrying out a radiological analysis that would highlight the major obstacles to place a straight press-fit stem, in particular the existence of a femoral curvature.
- Do not believe that all the cement can be removed without damaging the bone lesions further, if the cortical tissue is fragile due to stress-shielding or osteoporosis. In such situations there is a risk of incomplete removal of the cement.
- Do not insist on implanting a straight stem in a curved femur using the endofemoral route when a femoral flap is required or, similarly, believe that it would be possible to straighten a femoral curvature while preparing the femur with conical reamers.
- Do not aim to ensure a diaphyseal press-fit with a long stem via the endofemoral approach only: this can be very risky. The quality of a press-fit does not depend on the length of the implant but on how well the implant is wedged into place. It is always easier to ensure good wedging with a shorter stem when working near the anchoring area.
- Do not select an implant on the basis of the references provided by the reamer as this would frequently lead to the choice of an implant longer than necessary.
- Do not forget to keep a safety margin when choosing the height of the proximal component or the neck size of the ball head since forgetting this would lead to the risk of insufficient wedging at the time of implanting the definitive stem into place.
- Do not opt for implanting in two stages after choosing an endofemoral route.
- Do not impact the test prosthesis or the definitive stem by applying strong hammer blows without verifying its progression, or try to impact it in at all costs even when its progression is stopped. Doing this may lead to a fracture or the enclosure of the implant.
- Do not let the patient go home when weight-bearing is not allowed.

## Appendix 1

### Assembly of the Two Implant Components

The two implant components are assembled (proximal and distal component) to complete the Revitan Straight Stem (PFM-Revision) using a torque wrench. Depending on the strategy adopted by the surgeon, the assembly takes place in different ways: 1. in one step, in situ, after implantation of the distal component and with the help of a proximal trial implant, if a femoral bone flap has been prepared, or 2. in two steps outside the femur, if an intrafemoral approach has been chosen.

### The principle and use of the torque wrench


The principle of the torque wrench is based on cutting polyethylene shear pins using a cutting device, whereby the diameter of the shear pins has been chosen such that a torque of around 10Nm is always needed to cut through the pins.

**Note:** Assembling the two components of the prosthesis in situ using the endofemoral approach is a difficult task that requires a great deal of attention and should be avoided if possible.




This system guarantees a constant torque and offers the surgeon greater security. The torque wrench no longer needs calibrating.

The torque wrench is also used for tightening or loosening the safety nut.



Each manipulation (tightening) cuts two shear pins. Therefore, using a shear pins loader allows three tightening actions to be carried out (in principle two manipulations are needed when assembling).

A sterile shear pins loader is supplied with each proximal component. It is not possible to resterilize it.



- 1) Load the torque wrench.
  - Remove the cap (a) of the torque wrench (see illustrations 5, 6 and 7).
  - Prepare the shear pins loader (b). Each of the 6 polyethylene shear pins is prefitted on a shear pins loader made from polyethylene.

- 2) Insert the shear pins as far as they will go into the receptacle and turn the loader counterclockwise to release the pins from the plate.


- 3) Remove the loader.

- 4) Replace the cap and lock ("Lock" position).

- 5) After use, release the cap by pressing the release pin.

- 6) Turn the cap to the "Open" position.

- 7) Remove the cap and remove the "residual" or unused shear pins from their receptacle.



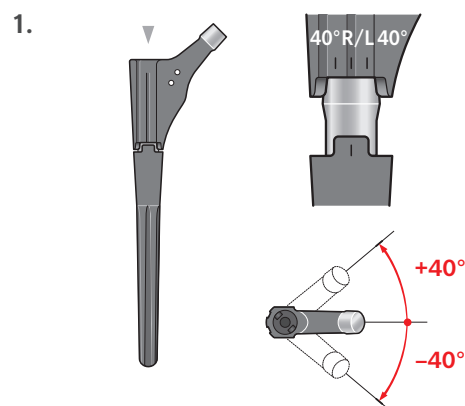


## Appendix 1

### Assembly of the Stem in One Stage (Extrafemoral)

#### 1. Position the definitive proximal component

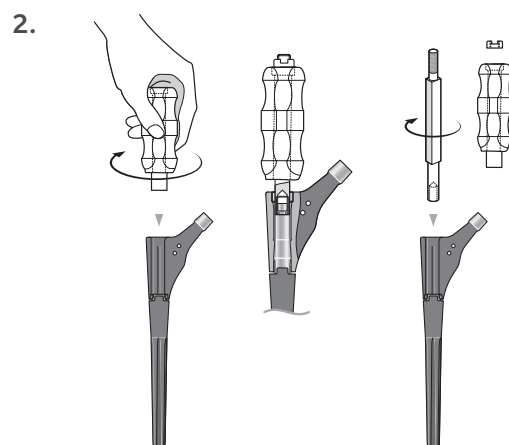
Before starting with the assembly of the two implant components, wash the taper, position the proximal component onto the Morse taper of the distal component by hand and set the desired antetorsion of the proximal component. This step must be done before any assembly force is applied to the stem. Once the antetorsion is chosen, push the two parts together by hand to give them stability before continuing with the assembly.



#### 2. Screw on the stem tensioner

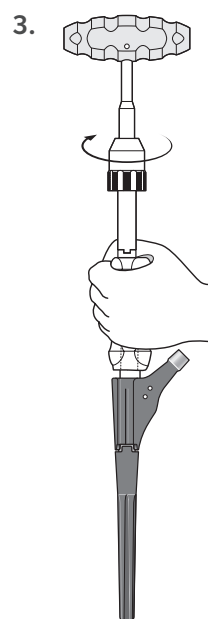
Screw the threaded rod of the tensioner onto the threaded part of the Morse taper and, if there is one, orientate the notch on the tensioner handle at the level of the neck.

To screw on the tensioner, hold it in the hand so that the threaded rod protrudes from the tensioner. It is also possible to remove the threaded rod from the handle.



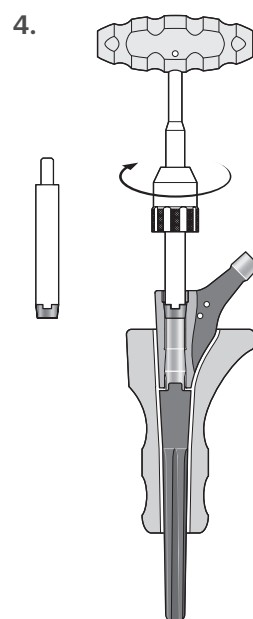
#### 3. Assemble of the two prosthetic components

Hold firmly the stem tensioner and tighten the assembly of the two components with the torque wrench. For this process the request of assistance is strongly recommended. Further, don't use the stem holder to maintain the implant in order to keep control of the antetorsion.



#### 4. Screw on the safety nut

Screw on the safety nut with the help of a setting instrument. When tightening with the torque wrench, the prosthesis is placed into a stem holder designed to neutralize rotational stresses.



## Appendix 1

### Assembly of the Stem in Two Stages (Intrafemoral)

#### 1. Assembly of the proximal trial part and implantation of the definitive distal component

After wedging in the definitive distal component, further trial reductions can be carried out if necessary by changing the sizes of the proximal trial part and changing its antetorsion (up to  $\pm 30^\circ$ ).

#### 2. Position the definitive proximal component

Before starting with the assembly of the two implant components, wash the taper, position the proximal component onto the Morse taper of the distal component by hand and set the desired antetorsion of the proximal component. This step must be done before any assembly force is applied to the stem. Once the antetorsion is set, push the two parts together by hand to give them stability before continuing with the assembly.

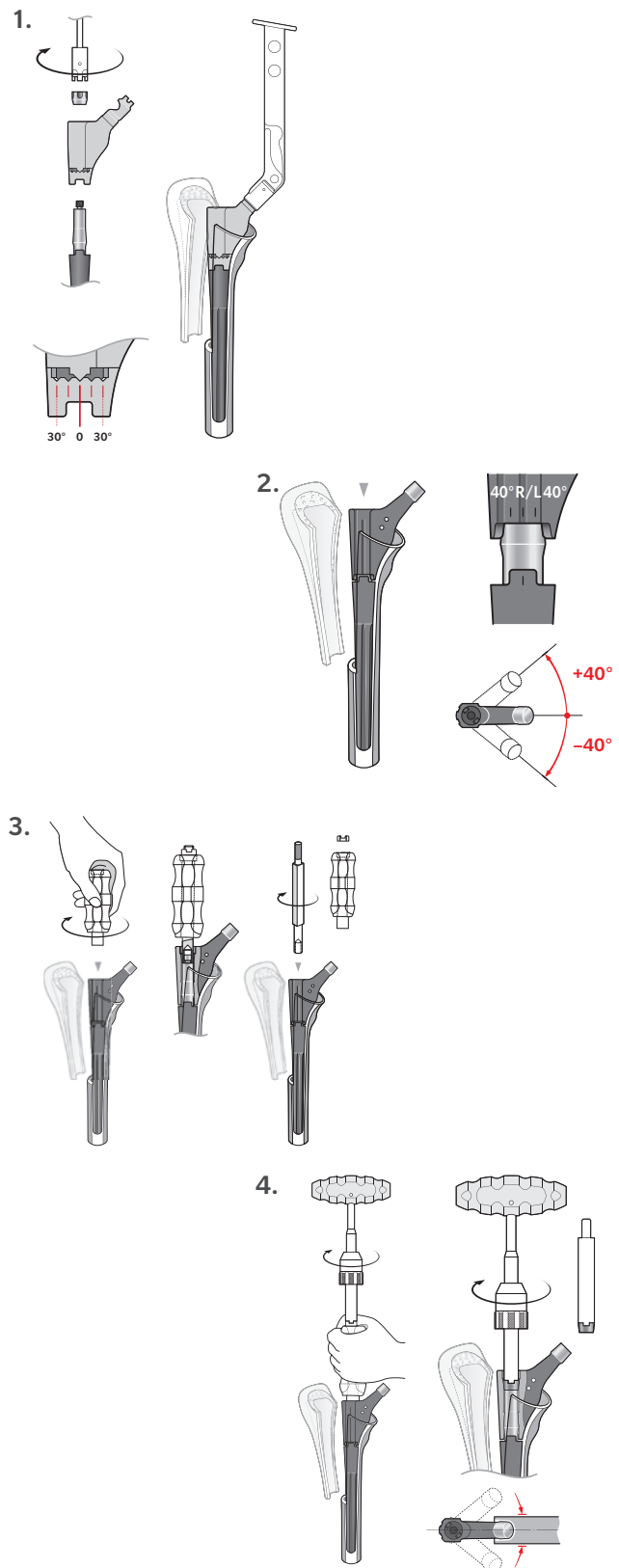
#### 3. Screw on the stem tensioner

Screw the threaded rod of the tensioner onto the threaded part of the Morse taper and, if there is one, orientate the notch on the tensioner handle at the level of the neck.

To screw on the tensioner, hold it in the hand so that the threaded rod protrudes from the tensioner. It is also possible to remove the threaded rod from the handle.

#### 4. Assembly of the definitive proximal component – screw on the safety nut.

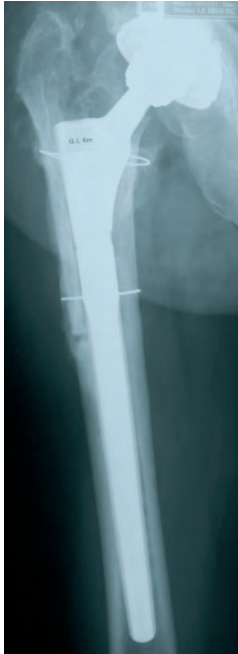
Hold firmly the stem tensioner and tighten the assembly of the two components with the torque wrench. For this process the request of assistance is strongly recommended. Finally the safety nut is screwed onto the threaded part of the Morse taper with the help of the setting instrument and tightened with the torque wrench. When tightening the conical nut, neutralize the torsion stresses caused by the torque wrench exerting counterpressure on the neck in the opposite direction to the tightening by hand or with the specially provided handle positioned over the neck of the implant.



## Appendix 2

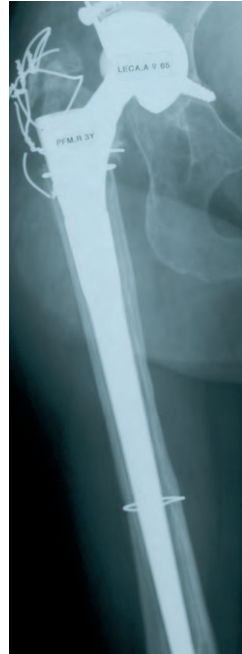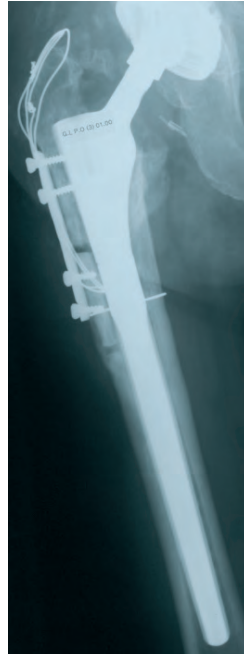
### Removal of a Revitan Straight Stem (PFM-Revision of the First and Second Generation)

Thanks to the development of a disassembly system, it is always possible to remove the proximal component. The removal of the distal implant component is more complicated, in particular in the case of a long stem, well anchored in the bone.



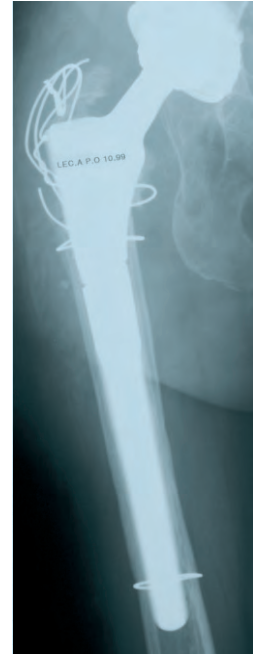Example. Bipolar subsidence: surgical revision with PFM-Revision stem and St. Nabor cup. X-ray after 6 months. Significant secondary subsidence of the femoral stem.

Extended trochanterotomy and replacement of the proximal components with a higher component with extra-long neck. The firm distal component is left in situ.



Example: Revision surgery in the case of a PFM-Revision stem and a double mobility cup because of iterative bipolar loosening (X-ray after 3 years).

Pseudoarthrosis on the greater trochanter. Easy removal of the femoral stem (distal component, 200 mm long) in one piece, which is replaced by a shorter stem with a larger diameter. Exchange of the double-mobility cup with an uncemented St. Nabor cup.



## Indications

Either only the proximal component alone or the whole implant is removed.

### Removal of the proximal component

The implant is stable. Removal of the proximal component is only necessary for the following reasons:

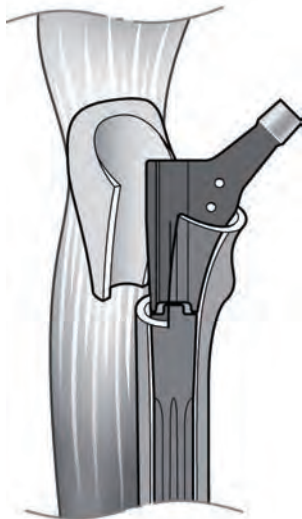- Access to the joint and cleaning the joint cavity (sepsis), or replacing a cup.
- Change of the proximal component, usually replacement of the component by a higher component because of strong secondary subsidence. More rarely, the antetorsion (recurring dislocation) has to be changed.

## Removal of the implant

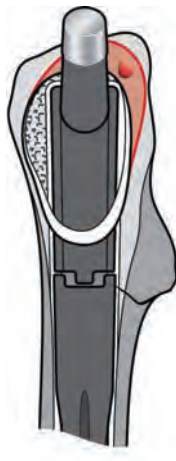### (proximal and distal component)

- If there is loosening of the implant with abnormal mobility, removal of the stem does not pose a problem. The prosthesis is removed in one piece using a simple extractor.
- If the stem is not loose, the implant should be removed in two steps. Remove the proximal component, then the distal component.

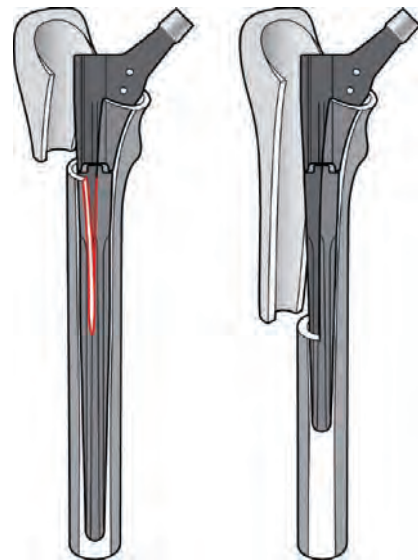
Removal of a firmly seated implant may be necessary in order to clean the medullary cavity (sepsis) or in order to change the implant where there is secondary subsidence that cannot be remedied by exchanging the proximal component.



Carry out a digastric trochanteric osteotomy whereby the insertions of the M. vastus lateralis at the base of the greater trochanter must be preserved.



If the endofemoral approach is selected, a wide lateral and posterior opening in the greater trochanter will be necessary.



A femoral bone flap is the safest option. In addition, it should be pointed out that it is easier to remove a short stem when the implant is not loose.

The diaphyseal release osteotomy option is especially indicated if the cortical bone is thick and of good quality (dense).

## Femoral approach(es)

It is possible to distinguish between two different situations: remove the proximal component alone, or remove both components

### Removal of the proximal component alone

If there are plans to remove the proximal component alone, it is strongly recommended to access the joint by carrying out an **extended osteotomy** of the greater trochanter, involving the lateral femoral cortex up to the proximal/distal component transition.

### Removal of the two implant components

If removal of both prosthetic components is planned (proximal and distal components), the surgeon has two options, depending on whether there is a loosening of the implant:

- **Loosened stem**


If the complete stem is loose (loosening of the two prosthetic components), only an **intrafemoral approach** is possible, whereby care must be taken to remove obstacles at the height of the greater trochanter.

- **Loosened stem**

With a short stem (length of the distal component 140 mm), prepare a **lateral bone flap** of a length of 15 to 20 cm.

In the case of a long stem (distal component 200 mm long): After carrying out an **extended trochanteric osteotomy** or a **bone flap** with an oscillating saw, carry out a **diaphyseal release osteotomy**.

It is also possible to perform a **femoral window** at the distal end of the implant to exert pressure (by hammering) from bottom to top with an instrument (such as a graft remover) to apply pressure to the distal end of the implant (see also page 49).



a) Disassembly instrument with a distal threaded part. (01.00409.801)

b) Threaded rod for disassembly instrument (01.00409.803).

c) Threaded sleeve for disassembly instrument (01.00409.816).

## Removal of the proximal component

### Attention

To remove the proximal component of an implant of a PFM-Revision of the first generation (REF: 21.16.09-XX, 20.16.XX-XXX, 01.0007X.XXX), other instruments are necessary. These are distributed as separate instruments.



### Dissassembly instructions

1) The torque wrench is in the locked position ("Lock").

2) Unscrew the safety nut with the torque wrench.

3) Screw the threaded sleeve (c) with the setting device (01.00409.815) on the threaded pin of the connection taper.

4) The disassembly instrument (a) is screwed to the proximal component via the thread.



5) Screw the threaded rod (b) that presses against the threaded sleeve (c) onto the disassembly instrument (a). The tension force guarantees the disassembly of the proximal component.

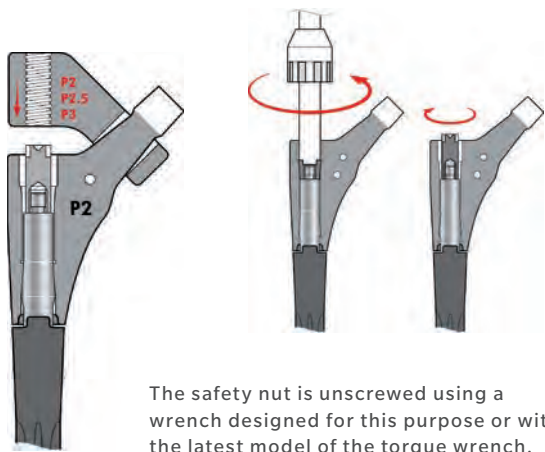
6a) Remove proximal component and

6b) unscrew the threaded sleeve.

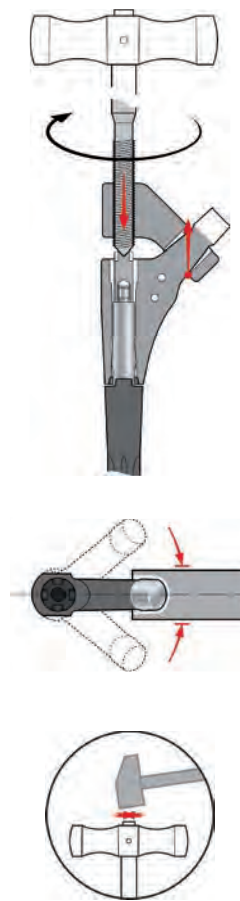Protect the connection taper with a compress if there is no intention of removing the distal component.

**Important:** The threads of the threaded rod and the disassembly instrument must be treated after each cleaning with a water-soluble product (for instance instrument milk or an equivalent lubricant) intended for surgical instruments, which are going to be sterilized (see IFU D011500279 and Manual on Instrument Care 97-5000-170-00).





The safety nut is unscrewed using a wrench designed for this purpose or with the latest model of the torque wrench.  
When placing the threaded sleeve, it is not necessary to lock it.



There are three disassembly components:

**P1** for P1 **old** model  
(old A1.P1)  
ref: 0100079013

**P2** for P1 **new** model  
ref: 0100079007

**P2 - P2,5 - P3** for the three  
other components  
ref: 0100079008

**P2 - P2,5 - P3** for the three  
other components

During disassembly, it is sometimes necessary to check the rotational stresses using a handle that rests on the Morse taper.

If the disassembly is not obtained with simple tightening, tap once on the handle of the threaded stem using a hammer.

## Removal of the proximal component (first generation)

### Important information

– the first generation implants have no thread on the proximal shoulder, therefore an auxiliary instrument is needed to disassemble the proximal component.

– When a change only concerns the proximal component, it is absolutely crucial that the surgeon has an implant of the same type because **a first generation proximal component is not compatible with a second generation distal component.**

### Placing the threaded sleeve

Screw on the safety nut and place a cylindrical threaded sleeve with a smaller diameter than that of safety nut.

ⓘ **Note:** This sleeve is used as a support for the threaded stem used for subsequent disassembly (see diagram below).

## Place the disassembly component

The disassembly component is an intermediate component that is placed on the neck and oriented so that the arrow engraved on it points toward the shoulder of the implant.

**Attention:** The disassembly component must match the proximal component in place.

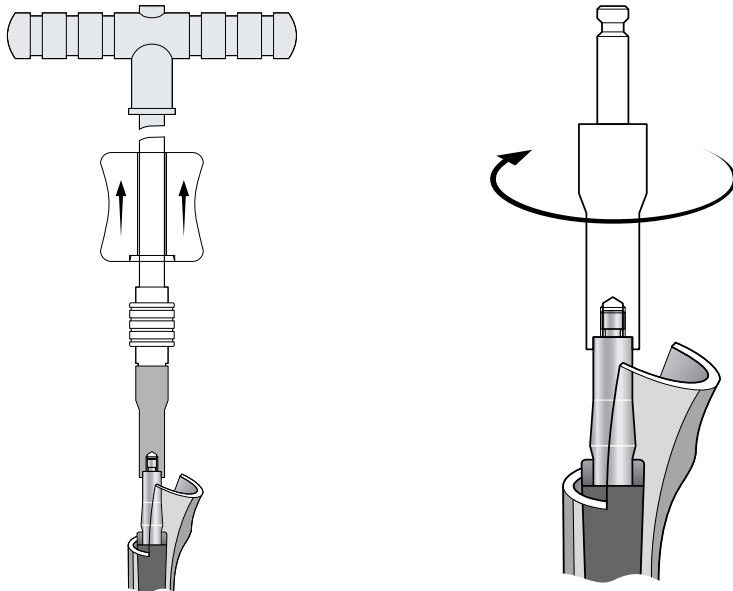
## Disassembly of the proximal component

Threaded stem with handle (ref: 01.00079.009) is screwed on the disassembly component and serves as a support to the threaded sleeve.

Tightening has the effect of disassembling the proximal component by means of the intermediary component, which is supported by the neck.

Once the proximal component has been removed, carefully clean the medullary canal and protect the connection taper with a compress if there is no intention of removing the distal component.





#### Important

It is advisable to make reasonable use of the sliding hammer and bear in mind that it is impossible to use this method to extract a stem that is well anchored in the cortical bone if it has not been released first. Insisting to forcefully can cause this step to have the sole effect of releasing the connection taper from the distal component.

## Removal of the distal component

It should be remembered that this stage of the surgery is always laborious when the distal component is perfectly osseointegrated, especially if the surgeon lacks the instruments specifically designed for this stage.

### Using a sliding hammer

- Remove the proximal component and release the proximal component of the distal component from its bone attachments using narrow, flexible bone chisels.
- Screw an intermediate component on the threaded part of the connection taper (ref: 01.00079.011).
- Adjust the sliding hammer to this intermediate component and tap along the axis of the distal component while controlling and maintaining the femur with forceps.
- If the distal component cannot be removed after a few taps with a hammer, additional measures must be taken such as longitudinal osteotomy, a window, a flap or the introduction of a flat chisel along the stem.

## Other possibilities

If the (reasonable) use of a sliding hammer does not permit the removal of the distal component without major difficulties (which is only possible in the case of precarious osteointegration), remain patient and use other measures, namely:

- Extend a diaphyseal release osteotomy and maintain a gap using bone chisels (the risk of a fracture is low if the bone cortex is of good quality and if a protective cerclage is performed beforehand)
- Make a longer flap if it is originally a short flap or an extended trochanterotomy.
- Free the bone-implant interface with pins or, better, bone chisels that are narrow, flat, long and preferably flexible.
- Create a distal window to exert extraction force, from bottom to top, using an intermediary component that rests on the distal end of the implant and which exerts pressure (hammer blows) by means of a window while remaining in the axis of the femur as much as possible.





All content herein is protected by copyright, trademarks and other intellectual property rights, as applicable, owned by or licensed to Zimmer Biomet or its affiliates unless otherwise indicated, and must not be redistributed, duplicated or disclosed, in whole or in part, without the express written consent of Zimmer Biomet.

This material is intended for health care professionals. Distribution to any other recipient is prohibited.

For indications, contraindications, warnings, precautions, potential adverse effects and patient counselling information, see the package insert or contact your local representative; visit [www.zimmerbiomet.com](http://www.zimmerbiomet.com) for additional product information.

Not for distribution in France.

Check for country product clearances and reference product specific instructions for use.

Zimmer Biomet does not practice medicine. This technique was developed in conjunction with health care professionals. This document is intended for surgeons and is not intended for laypersons. Each surgeon should exercise his or her own independent judgment in the diagnosis and treatment of an individual patient, and this information does not purport to replace the comprehensive training surgeons have received. As with all surgical procedures, the technique used in each case will depend on the surgeon's medical judgment as the best treatment for each patient. Results will vary based on health, weight, activity and other variables. Not all patients are candidates for this product and/or procedure. Rx only.

© 2019 Zimmer Biomet.

**For Ordering Information, please refer to 0738.1-OUS-en.**



**ZIMMER BIOMET**  
Your progress. Our promise.®

06.01109.012x - Rev. 5 2019-05



**Legal Manufacturer**

Zimmer GmbH  
Sulzerallee 8  
8404 Winterthur, Switzerland  
Telephone +41/ (0)52 262 60 70  
Fax +41/ (0)52 262 01 39

[www.zimmerbiomet.com](http://www.zimmerbiomet.com)

**CE 2797**

CE mark on a surgical technique is not valid unless there is a CE mark on the product label.