



**Zimmer®
Gender Solutions™
Natural-Knee®
Flex System**

Surgical Technique For
Fixed And Rotating Platform



Longterm clinical results — new options



Disclaimer

This document is intended exclusively for physicians and is not intended for laypersons.

Information on the products and procedures contained in this document is of a general nature and does not represent and does not constitute medical advice or recommendations. Because this information does not purport to constitute any diagnostic or therapeutic statement with regard to any individual medical case, each patient must be examined and advised individually, and this document does not replace the need for such examination and/or advice in whole or in part.

Information contained in this document was gathered and compiled by medical experts and qualified Zimmer personnel. The information contained herein is accurate to the best knowledge of Zimmer and of those experts and personnel involved in its compilation. However, Zimmer does not assume any liability for the accuracy, completeness or quality of the information in this document, and Zimmer is not liable for any losses, tangible or intangible, that may be caused by the use of this information.

Zimmer Gender Solutions Natural-Knee Flex System For Fixed and Rotating Platform

Table of Contents

System Overview	2
Design Rationale	2
Preoperative Planning	4
Component Sizing Compatibility	4
Patient Preparation	5
Incision and Exposure	5
Surgical Technique Summary	9
Bone Cuts	9
Preparing the Femur	10
Preparing the Tibia	11
Preparing the Patella	11
Surgical Approach	12
Locating the Medullary Canal	12
Cutting the Distal Femur	13
Drilling the Distal Femoral Holes and Calibrating the Femur	15
Finishing the Femur	16
Preparing the Proximal Tibia	19
Using the Extramedullary Tibial Technique	19
Setting the Rotation	19
Setting the Varus/Valgus Angle of the Tibial Cut	19
Setting the Posterior Slope	20
Level of Resection	20
Cutting the Tibia	20
Sizing and Drilling the Proximal Tibia	21
Preparing the Patella	23
Trial Reduction	25
Implanting the Components	26
Pressfit Fixed Tibial Baseplate	26
Pressfit Rotating Platform Tibial Baseplate	26
Cemented Tibial Baseplate	26
Tibial Insert Fixed Bearing	27
Tibial Insert Mobile Bearing	27
Femoral Component	27
Patella	27
Final Steps	28
Postoperative Care	28
Intramedullary Tibial Option	28
Using the Tibial Spacer Option	30
Balancing the Soft Tissue	31
Ultracongruent Component Patient Selection	32

System Overview

Since 1985, the *Natural-Knee*® System has been used successfully to treat over 500,000 patients worldwide. Long-term clinical results confirm that the *Natural-Knee* System's design considerations result in improved motion and stability, and promote normal alignment and stable fixation of the implant. The mean Modified Hospital for Special Surgery knee score improved from 59.1 ± 13.2 preoperatively to 97.8 ± 4.7 postoperatively at 10-to-14 years follow-up.¹

Specific Operative Techniques

- Anatomic posterior tibial slope resections provide optimal distribution of stress on the bone structure, maximizing the load carrying capacity of cancellous bone.
- Intraoperative use of bone slurry at the bone/Cancellous-Structured Titanium (CSTi™) Porous Coated-implant interface provides up to three times the amount of bone ingrowth at the interface as compared to specimens implanted without bone slurry.^{1,2}
- Posterior-referencing femoral resection results in matched flexion and extension gaps, which help with natural rollback, natural ROM, and a potential for reduced polyethylene wear.
- Patellar-measured resection followed by component medialization reduces the need for lateral retinacular releases without exceeding the original patellar thickness.

Device Design

- The *Gender Solutions Natural-Knee* Flex System is designed for use with *Natural-Knee* II tibial baseplates. These innovative asymmetrical tibial baseplates provide optimal coverage of the tibial plateau, creating excellent stability with less impingement due to overhang, and ultimately replicate natural anatomy.
- The Ultracongruent articular surface provides posterior stabilization without bone sacrifice.³ This innovative design provides continuous stabilization throughout the range of motion.
- A deepened trochlear groove prevents excessive load on the patellar component while providing excellent ROM.

Material Technology

- Revolutionary CSTi Porous Coating features a cobalt-chrome femoral articulating surface combined with the biocompatibility of titanium coating, resulting in stable fixation and outstanding clinical results.^{4,5} Postmortem studies support the biocompatibility of CSTi Coating and consistent bony ingrowth.¹
- Tibial baseplates are constructed from either titanium or cobalt chrome, providing surgeons a choice.

Design Rationale

Restoration of Anatomy

Surgery using the *Gender Solutions Natural-Knee* Flex System creates a true resurfacing by referencing the least-involved portion of the femoral condyle, the least-involved portion of the tibial plateau, and the thickest portion of the medial facet of the patella, restoring kinematics and the anatomic joint line.

Knee rotation testing and computer modeling show that the level of resection relative to the amount of bone replaced by the prosthesis on the distal femur plays an important role in knee kinematics and ligament balance.

Bone resection, followed by an equal amount of prosthetic replacement, provides the knee with near normal varus-valgus and rotational stability throughout the full range of motion.

A stepped anterior chamfer cut allows bone resection and replacement with a deeply grooved femoral component, anatomically restoring the level of the trochlear groove. As a result, patellofemoral joint stability is achieved, requiring fewer or less extensive lateral releases. In addition, the patellofemoral joint line is maintained, avoiding increased patellofemoral compressive forces.

With the *Gender Solutions Natural-Knee* Flex System, the tibial cut is made parallel to the joint line on the anterior/posterior plane to avoid camming or laxity during extension and flexion.⁶ Since the normal posterior tilt of the tibia is not a constant angle (range 4-12°), the tibial cut must be adjustable in order to reproduce each patient's normal posterior slope. If the posterior slope is fixed or if the tibia is cut perpendicular to the tibial shaft axis, the normal kinematics of the knee may not be simulated.

Cutting the tibia parallel to the patient's natural posterior slope may improve the load-carrying capacity of the supporting bone. Ultimate compressive strength improved 40% when bone cuts were made parallel to the joint versus perpendicular to the tibial shaft axis.⁶ If the tibial cut closely matches the anatomic posterior slope, anterior subsidence is avoided.

The proximal tibia is usually 4-5mm smaller on the lateral side than on the medial side,⁷ therefore, an asymmetric replacement provides the best coverage of the proximal tibia without soft tissue impingement. Symmetric replacements, however, require either under filling the medial side or overhanging the lateral side.

Restoration of Normal Alignment

Normal alignment usually implies that the mechanical axis, from the center of the hip to the center of the ankle, will pass through the center of the knee. The implant should be positioned perpendicular to that line. Correct positioning is usually accomplished by cutting the tibia perpendicular or in slight varus in the frontal plane and by cutting the distal femur in 5-6° of valgus relative to the anatomic axis (Fig. 1).

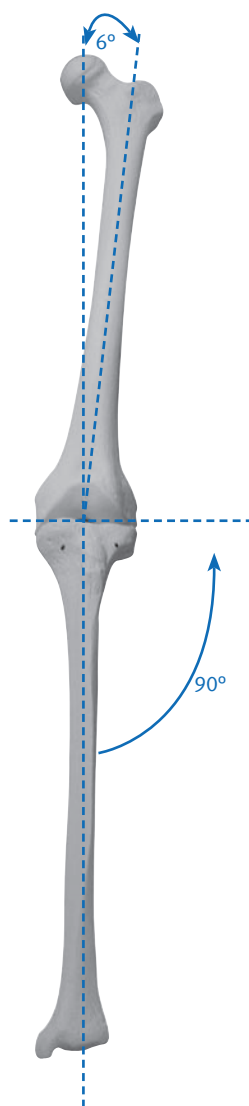


Fig. 1

A standard 5-6° valgus cut of the femur is recommended for two reasons. First, the anatomic-mechanical axis angle can be measured from a radiograph, but it may be inaccurate by 1-2° because of rotational inconsistency. Second, the true anatomic axis may be off by 1-2° using intramedullary instruments if the starting point on the distal femur is too medial or lateral, or if the intramedullary rod is not perfectly centered in the medullary canal.

For marked anatomic variation (e.g., malunion), instrumentation can be used with an external alignment tower pointing toward the preoperatively marked femoral head. For minor anatomic variation and intraoperative correction of the distal femoral or proximal tibia cuts, a $\pm 2^\circ$ block is available, or the MIS distal femoral alignment guide can be set for a 4°, 5°, or 6° valgus angle.

1. Hofmann AA, Evanich JD, Ferguson RP, Camargo MP. Ten- to 14-year clinical follow-up of the cementless Natural Knee system. *Clin Orthop*. 2001 Jul; (388): 85-94.
2. Hofmann AA, Bloebaum RD, Rubman MH, Bachus KN, Plaster R. Microscopic analysis of autograft bone applied at the interface of porous-coated devices in human cancellous bone. *Int Orthop*. 1992 Dec; 7(4): 483-93.
3. Hofmann AA, Tkach TK, Evanich CJ, Camargo MP. Posterior stabilization in total knee arthroplasty with use of an ultracongruent polyethylene insert. *J Arthroplasty*. 2000 Aug; 15(5): 576-83.
4. Bonding of porous Ti to CoCr—the Sinterlock process. Zimmer
5. Baldwin JL, El-Saied MR, Rubinstein RA, Jr. Uncemented total knee arthroplasty: report of 109 titanium knees with cancellous-structured porous coating. *Orthopedics*. 1996 Feb; 19(2): 123-30.
6. Hofmann AA, Bachus KN, Wyatt RW. Effect of the tibial cut on subsidence following total knee arthroplasty. *Clin Orthop*. 1991 Aug; (269): 63-9.
7. Smith J, Hofmann AA. Morphology of the proximal tibia in the arthritic knee. Zimmer

Increased Fixation

A well-fixed and stable implant contributes significantly to the long-term success of the total knee arthroplasty. *CSTi* Porous Coating provides potential for optimal ingrowth fixation.^{1,8,9,10} Each *Gender Solutions Natural-Knee* Flex System component is secured with smooth pegs (as opposed to porous-coated pegs) to help prevent stress shielding and to increase stabilization (except the CoCr Baseplate, which has no pegs). The femoral and tibial components feature either *CSTi* Porous Coating for pressfit, or gritblasting for improved bone cement/implant fixation.

Two titanium cancellous bone screws augment the component's four peripherally-placed pegs and central cruciate stem, enhancing tibial fixation of the asymmetric resurfacing and stemmed tibial components.^{7,11} The central stem improves fixation in softer bone (e.g., rheumatoid arthritic patients or osteoporotic patients). Resurfacing components provide excellent fixation in hard bone (e.g., osteoarthritic males and patients with prior high tibial osteotomies).¹²

Countersinking the 10mm metal-backed components 2-3mm improves fixation of the patella.¹³ Patellar components come in four sizes, including a 10mm thick metal-backed (*CSTi* Porous Coated) and 10mm thick all-poly patella. An 8mm thick all-poly patella is available for thinner (less than 22mm) patellas, but should not be countersunk. Patellar component fixation is augmented by three peripherally-placed pegs.

Preoperative Planning

Obtain 36 in. or 52 in. standing anteroposterior and lateral radiographs of the extremity, as well as a sunrise view of the patella. The entire femur should be visualized to rule out any structural abnormality, as the distal femoral cut will be referenced from an intramedullary rod in the medullary canal.

If the intramedullary tibial instruments are used, the entire tibia should be visualized to identify any varus or valgus bowing, and the appropriate tibial entry point planned.

Templating for size is most accurate on the lateral radiograph since many patients present with a flexion contracture that distorts magnification on the anteroposterior radiograph. The intraoperative management of tibial defects is planned using bone graft, cement and/or tibial spacers.

The degree of constraint in the tibial articular surface may be planned, such as the use of the ultracongruent articular surface for more constraint in patients with posterior cruciate ligament (PCL) deficiency or in the unstable varus or valgus knee.

Component Sizing Compatibility

Patellae

All sizes and thicknesses of *Natural-Knee* Flex patellae are compatible with all sizes of *Natural-Knee* Flex femurs.

Fixed Bearing Tibial Articular Surfaces

There are three sizes of tibial articular surfaces in left and right configurations. The femoral components are compatible with tibial articulating surfaces based on one-up and one-down sizing as shown in the chart below. For example, a size 1,2 articular surface mates with a size 1 or a size 2 baseplate and is compatible with a size 0, size 1, size 2, or size 3 femoral component.

Fixed Bearing			
Femur	0,1	0,1,2,3	2,3,4,5
Articulating Surface	00,0	1,2	3,4,5

Rotating Platform (RP) Tibial Articular Surfaces

There are six sizes of tibial articular surfaces in left and right configurations. The femoral components are compatible with tibial articulating surfaces based on one-up and one-down sizing as shown in the chart below. For example, a size 1 articular surface mates with a size 1 RP baseplate and is compatible with a size 0, size 1, or size 2 femoral component.

Rotating Platform (RP)						
Femur	0,1	0,1,2	1,2,3	2,3,4	3,4,5	4,5
Articulating Surface	0	1	2	3	4	5

8. Bachus, KN. Canine and human cancellous bony ingrowth into Ti and CoCr porous-coated plugs implanted into the proximal tibia. *Ortho Trans.* 1988; 12(2): 380.
9. Leland R, Hofmann AA, Chowdhary, R. Biocompatibility and bone response of human cancellous bone to a Ti porous-coated CoCr implant. *Society of Biomaterials Meeting: AZ*; 1991.
10. Hofmann AA. Response of human cancellous bone to commercially pure Ti and CoCr alloy porous-coated cylinders. *Clinical Materials.* 1993; (14): 101-15.

11. Hofmann AA. Total knee replacement using the *Natural Knee* system. *Tech in Orthop.* 1987; 1(4): 1-17.
12. Hofmann AA. Stemmed versus resurfacing tibial components in total knee arthroplasty. *Knee Society Interim Meeting: IL*; 1991.
13. Evanich CJ, Tkach TK, von Glinski S, Camargo MP, Hofmann AA. Six- to 10-year experience using countersunk metal-backed patellas. *J Arthroplasty.* 1997 Feb; 12(2): 149-54.

Patient Preparation

To prepare the limb for MIS total knee arthroplasty, adequate muscle relaxation is required. This may be accomplished with a short-acting, nondepolarizing muscle relaxant. The anesthesiologist should adjust the medication based on the patient's habitus and weight, and administer to induce a complete muscle paralysis for a minimum of 30-40 minutes. This will facilitate the eversion of the patella, if desired, and minimize tension in the remaining quadriceps below the level of the tourniquet. It is imperative that the muscle relaxant be injected prior to inflation of the tourniquet. Alternatively, spinal or epidural anesthesia should produce adequate muscle relaxation.

Apply a proximal thigh tourniquet and inflate it with the knee in hyperflexion to maximize that portion of the quadriceps that is below the level of the tourniquet. This will help minimize restriction of the quadriceps and ease patellar eversion.

Once the patient is draped and prepped on the operating table, determine the landmarks for the surgical incision with the leg in extension.

Because the knee must be repositioned multiple times and in multiple positions during surgery, the use of a leg positioner is recommended. A lateral trochanteric pad allows for excellent stability of the extremity.

Incision and Exposure

The incision may be made with the leg in extension or flexion depending on surgeon preference. The minimum length of the incision is dependent on the size of the femoral component and the ability to obtain adequate exposure in order to perform the surgery accurately and expeditiously. Although the goal of a MIS technique is to complete the surgery with an approximately 10cm-14cm incision, it may be necessary to extend the incision if visualization is inadequate or if subluxation of the patella is not possible without the risk of avulsion at the tibial tubercle. If the incision must be extended, it is advisable to extend it gradually and only to the degree necessary. The advantage of a MIS technique is dependent on maintaining the extensor mechanism insertion.

Begin making a slightly oblique parapatellar skin incision beginning at the superomedial corner of the patella, and extend it approximately 10cm-12cm to the medial center of the tibial tubercle. Be careful to avoid disruption of the tendon insertion. Divide the subcutaneous tissue to the level of the retinaculum.

The arthrotomy is the surgeon's choice. Options include a subvastus approach, mid-vastus approach, or a mini medial arthrotomy. Also, depending on surgeon preference, the patella can either be everted or subluxed. Eversion of the patella may require a longer skin incision and more detachment of the quadriceps to the patella. Rehabilitation may be facilitated by the least invasion of the quadriceps muscle.

Technique Tip: Using electrocautery to complete the exposure will help minimize bleeding after deflation of the tourniquet, as well as late muscle bleeding.

MIS Medial Parapatellar Arthrotomy

Minimally invasive total knee arthroplasty has become a popular procedure with surgeons using a variety of surgical exposures including the limited medial parapatellar arthrotomy; the midvastus approach; subvastus approach. The MIS medial parapatellar arthrotomy is a versatile approach that can be easily converted to a traditional approach if necessary. Advantages of this technique include diminished post-operative morbidity, less post-operative pain, decreased blood loss, and an earlier functional recovery.¹⁴⁻¹⁸ However, while limiting the exposure, the integrity of the total knee arthroplasty must not be compromised. Following specific guidelines in patient selection and surgical technique, the clinical outcome can be predictable.

The MIS medial parapatellar arthrotomy is a versatile approach because it evolved from the traditional approach performed by most surgeons. The learning curve for this technique is short as surgeons gradually reduce the length of the skin incision and the arthrotomy into the quadriceps tendon in order to gain exposure of the knee joint. With lateral subluxation of the patella, instead of eversion, both the femur and tibia can be visualized without extending the arthrotomy high into the quadriceps tendon.

Begin by making a straight anterior midline incision from the superior aspect of the tibial tubercle to the superior border of the patella. The skin incision is made as small as possible in every patient, but should be extended as needed during the procedure to allow for adequate visualization and avoidance of excess skin tension. Skin under the appropriate tension should form a 'V' at the apices. If the skin forms a 'U', the incision should be lengthened.

Following subcutaneous dissection, develop full-thickness medial and lateral flaps to expose the extensor mechanism. Release of the deep fascia proximally beneath the skin and superficial to the quadriceps tendon facilitates mobilization of the skin and enhances exposure. In addition, with the knee in flexion the incision will stretch an average of 3.75cm due to the elasticity of the skin allowing broader exposure.¹⁸

The goal of minimally invasive surgery is to limit the surgical dissection without compromising the procedure. The MIS medial parapatellar arthrotomy is a shortened version of the traditional approach. Initially incise the quadriceps tendon for a length of 2-4cm above the superior pole of the patella. The arthrotomy should be of a sufficient length to sublux rather than evert the patella laterally or if the patella tendon is at risk of injury, extend the arthrotomy proximally until adequate exposure is achieved (Fig. 2).

Once the exposure is achieved, the bone preparation begins with the knee flexed at 90°, retractors are placed both medially and laterally to help aid in exposure, avoid undue skin tension, and to protect the collateral ligaments and the patella tendon. In order to aid visualization and avoid undue tension to the skin, the surgical assistants are instructed in proper placement of retractors and positioning of the knee. This will create a "mobile window" of exposure. With experience, it will become obvious that the bone preparation and resection is performed at different angles of knee flexion. In addition as the bone is resected from the proximal tibia and distal femur, there is more flexibility to the soft tissue envelope and greater exposure is achieved.

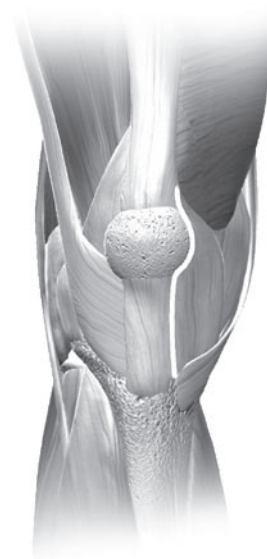


Fig. 2

14. Hofmann AA, Tkach TK, Evanich CJ, Camargo MP. Posterior stabilization in total knee arthroplasty with use of an ultracongruent polyethylene insert. *J Arthroplasty*. 2000 Aug; 15(5): 576-83.
15. Bonding of porous Ti to CoCr—the Sinterlock process. Zimmer
16. Baldwin JL, El-Saied MR, Rubinstein RA, Jr. Uncemented total knee arthroplasty: report of 109 titanium knees with cancellous-structured porous coating. *Orthopedics*. 1996 Feb; 19(2): 123-30.
17. Hofmann AA, Bachus KN, Wyatt RW. Effect of the tibial cut on subsidence following total knee arthroplasty. *Clin Orthop*. 1991 Aug; (269): 63-9.
18. Smith J, Hofmann AA. Morphology of the proximal tibia in the arthritic knee. Zimmer

MIS Midvastus Approach

The capsular incision from the superomedial corner of the patella distally to the tissue overlying the medial tibia is routine in all medial capsular approaches. Preserve approximately 1cm of peritenon and capsule medial to the patellar tendon to facilitate complete capsular closure. Split the superficial enveloping fascia of the quadriceps muscle proximally over a length of several centimeters to identify the vastus medialis obliquus (VMO) fibers inserting into the extensor mechanism. This will help mobilize the quadriceps and allow for significantly greater lateral translation of the muscle while minimizing tension on the patellar tendon insertion.

The approach becomes “midvastus” at a point proximal to the superomedial pole of the patella. Variations on the angle at which the proximal part of the capsular incision enters the muscle belly of the VMO will result in various amounts of the muscle being incised as well as variation in the amount of force required to sublux the patella laterally. Additional variables include the actual point of insertion of the VMO fibers into the patella. This insertion is variable and can take place very high (actually on the quadriceps tendon proper and not on the patellar border at all), or lower (at the midpoint of the medial patellar border), or anywhere in between. The higher the insertion of the VMO, the shorter the length of the incision into the muscle proper. The lower the insertion, the more a “low incision” into the VMO will make the exposure more like a subvastus approach and may make subluxation of the patella more difficult. It is very important to carry the capsular incision all the way to the superior border of the patella before incising the muscle belly of the VMO.

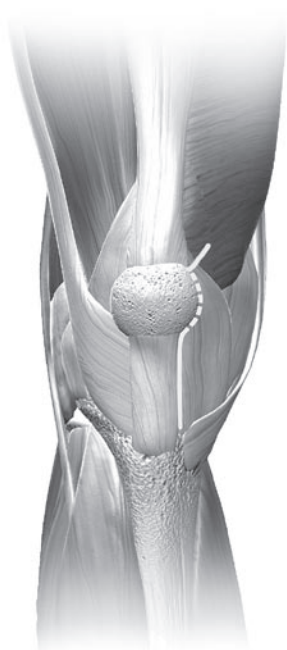


Fig. 3

After identifying the characteristics of the VMO insertion, the vastus medialis obliquus muscle belly is split by sharp dissection approximately 1.5cm-2cm (Fig. 3). The superficial muscle has only a flimsy investing fascia and this fascia, along with the muscle belly, may be split by blunt dissection; however, the deepest layer of muscle is adherent to the more robust fascia of the VMO, which should be incised sharply.

The use of a rake to retract the capsular edges medially will reveal variable amounts of synovium. The synovium may be minimal, exuberant and inflamed, or fibrotic. Removal of excessive synovium from the medial border of the capsule at the most proximal part of the exposure distally will improve exposure and, if the synovium is fibrotic, will also reduce the tension required for exposure.

Routine medial capsular exposure proceeds by sharp dissection and removal of the anterior third of the medial meniscus, and is followed by sharp dissection of the deep medial

collateral ligament from its insertion on the proximal tibia. This occurs while the knee is flexed but may be carried out in extension at the surgeon's discretion. This is adequate for exposure of the medial side of the knee. The experienced surgeon may want to proceed with any medial capsular releases that are predicted to be necessary to align the limb and balance the knee, or these maneuvers may be saved for later in the procedure. At this point the medial capsular retractors are removed from the wound for exposure of the lateral side.

The knee is in extension for the preliminary portion of the lateral knee exposure. First, the mobility of the patella is determined. Rakes are used to gently mobilize the patella. Mobilization may be inhibited, however, by fibrosis of the fat pad inferiorly or scarring of the suprapatellar synovium superiorly. Both conditions can be established by careful palpation and appropriate releases performed by sharp dissection. Large patellar osteophytes may be removed at this point to make patellar mobilization easier. If partial eversion—bringing the patella perpendicular to the joint (90°)—is possible, no further dissection distally in the fat pad or proximally via suprapatellar synovectomy is needed. With the patella partially everted, the bulk of the fat pad can be debrided at the surgeon's discretion. The tighter the exposure, the more fat pad debridement will facilitate visualization and cutting guide placement.

The lateral joint space is then exposed by flexing the knee. It is important to avoid disrupting the extensor insertion by gently mobilizing the patella, slowly flexing the joint, and externally rotating the tibia while applying gentle pressure on the patella. An excessively thick patella may make exposure more difficult and it may help to make a standard

patellar cut to decrease the thickness of the patella. If this is necessary, the patella must be protected from retraction forces with an appropriate patellar protection device.

Once the patella is subluxed, one or two standard-size Hohmann retractors placed along the lateral flare of the tibial metaphysis will maintain the eversion of the patella and the extensor mechanism. If present, the anterior cruciate ligament is released. A subperiosteal dissection along the proximal medial and lateral tibia to the level of the tibial tendon insertion can be performed as needed to mobilize the tissue envelope and to help adequately expose the bone. Release of the lateral patellofemoral ligament and/or limited release of the lateral capsule (less than 5mm) may occasionally, but rarely, be required to help minimize tension on the extensor mechanism. Pointed Hohmann and knee joint retractors may be used to mobilize the skin and arthrotomy incision to create the “mobile window” through which the remainder of the procedure is performed.

It is very important to maintain observation of the patellar tendon and the wound margins throughout the procedure to ensure that tension on these tissues are kept to an acceptable level.

MIS Subvastus Approach

Becoming accustomed to operating through a small incision and adopting the concept of a mobile window may be facilitated by starting with a shortened medial parapatellar arthrotomy. This will help to improve visualization of the anatomy during the initial stages of becoming familiar with an MIS approach.

When comfortable with the MIS medial parapatellar approach, performing the arthrotomy through a midvastus approach will help preserve the quadriceps tendon and a portion of the medial muscular attachment. As this procedure becomes more familiar, the level of the midvastus incision should be lowered to maintain more muscle attachment.

The subvastus arthrotomy provides excellent exposure through an MIS incision. The oblique portion of the incision starts below the vastus medialis obliquus (VMO) attachment and will preserve all the medial muscle attachments, including the retinacular attachment to the medial patella. A key aspect of the subvastus approach is that it is not necessary to evert the patella. This helps avoid tearing of the muscle fibers and helps maintain muscle contraction soon after surgery.

The longitudinal incision should extend only to the point of insertion of the VMO inferiorly, not to the proximal pole. Begin the arthrotomy at the medial edge of the tubercle and extend it along the border of the retinaculum/tendon to a point on the patella corresponding to 10 o'clock on a left knee or 2 o'clock on a right knee. Then continue the incision obliquely 1 cm-2cm just below and in line with the VMO fibers (Fig. 4). Do not extend the oblique incision beyond this point as it creates further muscle invasion without providing additional exposure.

Perform a medial release according to surgeon judgment, depending on the degree of varus or valgus deformity. To facilitate a medial release, place the knee in extension with a rake retractor positioned medially to provide tension that will assist in developing this plane. For valgus deformities, consider

performing a more conservative medial release to avoid over-releasing an already attenuated tissue complex.

With the knee in extension and a rake retractor positioned to place tension on the patella, remove the retropatellar fat pad. Then excise a small piece of the capsule at the junction of the longitudinal and oblique retinacular incisions. This release allows the patella to retract laterally. Undermine the suprapatellar fat pad, but do not excise it. This helps ensure that the Femoral A/P Sizer will be placed directly on bone rather than inadvertently referencing off soft tissue, which may increase the femoral size measurement.

Placement of a lateral retractor is very important for adequate retraction of the patella. With the knee extended, slip the retractor into the lateral gutter and lever it against the retinaculum at the superomedial border of the patella. As the knee is flexed, the patella is retracted laterally to provide good visualization of the joint.

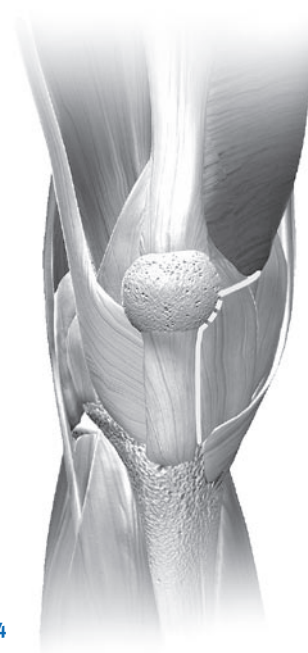


Fig. 4

Surgical Technique Summary

Bone Cuts

Bone resorption and connective tissue formation occur when bone is surgically traumatized and heated to above 45° centigrade for longer than one minute. To control thermal injury, cool the saw blade using constant irrigation when making bone cuts.¹⁹ All femoral bone cuts are made with the Flex 4-in-1 Femoral Finishing Guide (Fig. 5).



Fig. 5

To ensure that a perfectly flat surface has been created, use a saw guide or an auxiliary cutting block to sight all bone cuts in two planes (Fig. 5a).



Fig. 5a

1/2 in. wide and 1 in. wide by .050 in. (1.27mm) thick saw blades are required for femoral and tibial cuts. With MIS-friendly cut guides, the use of a flared blade facilitates the necessary bone cuts. A .040 in. (1mm) thick saw blade is required for use with the patellar osteotomy guide and the tibial spacer cut guide. The sharpness of a new blade decreases both operating time and injury to the bone.

Each cutting block can be stabilized first by drilling with a 5 in. x 1/8 in. (3.2mm) drill bit that remains loaded in the Jacob's chuck. The drilled holes are then filled with 3 in. x 1/8 in. smooth pins. This is especially important in softer bone. The first calibrated mark on the drill point indicates the drilling depth of the tibial baseplate pegs; the second mark is for the metal-backed patella pegs (Fig. 6).

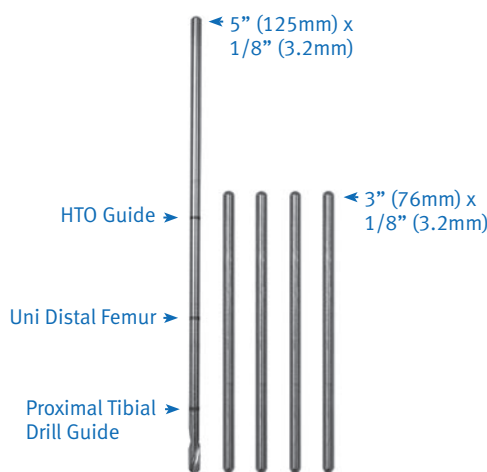
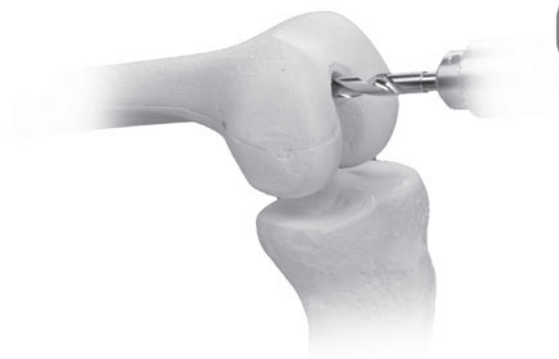

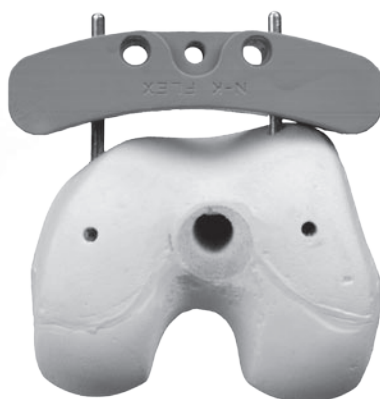Fig. 6

19. Krause WR, Bradbury DW, Kelly JE, Lunceford EM. Temperature elevations in orthopaedic cutting operations. J Biomech. 1982; 15(4): 267-75.


Preparing the Femur



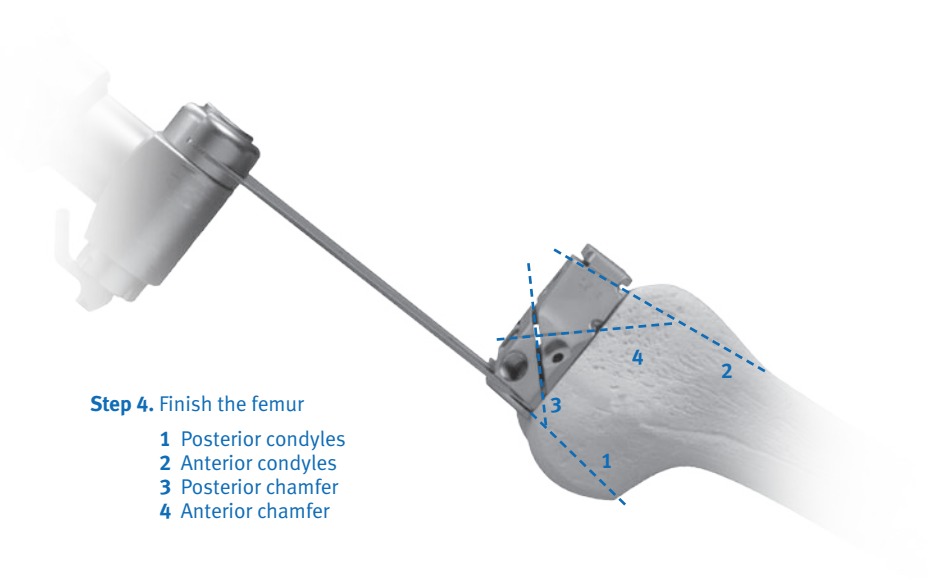
Step 1. Locate the intramedullary canal



Step 2. Cut the distal femur



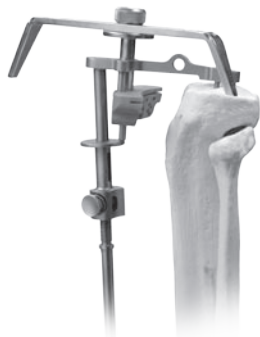Step 3. Drill distal femoral holes and calibrate the femur



Step 4. Finish the femur

- 1 Posterior condyles
- 2 Anterior condyles
- 3 Posterior chamfer
- 4 Anterior chamfer

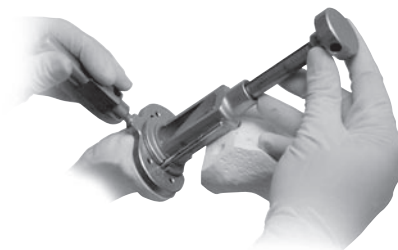
Preparing the Tibia



Step 1. Cut the proximal tibia



Step 2. Size and drill the proximal tibia

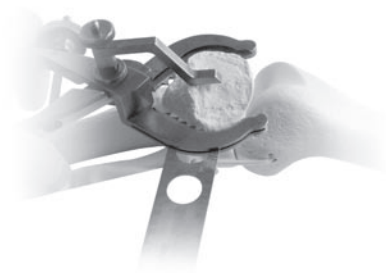

Step 3. Broach the tibia (for stemmed components only)

Preparing the Patella




Step 1. Determine the patellar thickness



Step 2. Osteotomize the patella (0.040 in. thick blade)



Step 3. Plane the patella



Step 4. Drill holes for the pegs

Surgical Approach

Locating the Medullary Canal

Make a 5/16 in. (8mm) hole in line with the femoral shaft (Fig. 7a).

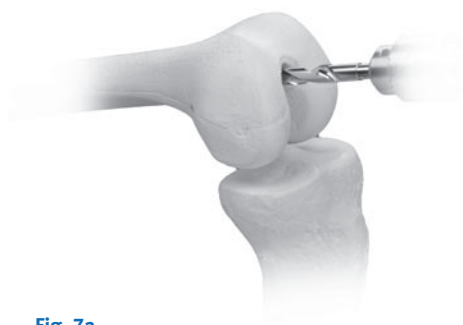

Fig. 7a

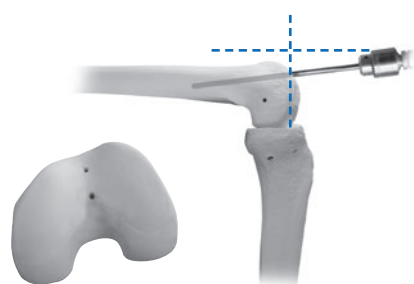
Center the starting point distally on the trochlear groove 1-2mm anterior to the true roof of the intercondylar notch (Fig. 7b).



Correct

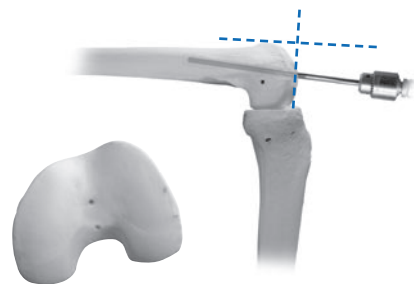
Fig. 7b

The placement of the hole determines the flexion/extension position of the femoral component on the femur. The drill hole must be aligned with the femoral shaft in both the frontal and lateral planes. Incorrect anterior drill hole placement leads to extension of the femoral component with potential notching of the anterior cortex. Incorrect posterior drill hole placement leads to flexion of the femoral component (Figs. 7c and 7d).



Incorrect

Fig. 7c



Incorrect

Fig. 7d

NOTE: Slightly toggle the drill upon exiting to center the intramedullary rod and vent the medullary canal in order to prevent pressurization.

Slowly and fully insert the Fluted 5/16 in. Intramedullary Rod into the isthmus (Fig. 8). If the rod does not slide easily into the canal, reassess the orientation of the hole to ensure that it is in line with the femoral shaft. Aim slightly lateral to avoid running into the medial cortex.



Fig. 8

Cutting the Distal Femur

Set the angle for the valgus cut on the Distal Femoral Alignment Guide for 4, 5, or 6 degrees. The holes are marked at either the top or bottom of the holes on the Alignment Guide with an 'L' or an 'R' and a 4, 5, or 6, designating left or right and the degree of the valgus cut.

Dial the medial or lateral adjustable screw down to the defective distal femoral condyle (Fig. 10). If both condyles are defective (e.g., a patient with rheumatoid arthritis), slightly dial down both adjustable screws to compensate for the lost cartilage.

Before stabilizing the MIS Distal Femoral Alignment Guide, line up the posterior portion of the guide with a line that runs parallel to the posterior femoral condyles in order to achieve the correct rotational alignment of the guide (Fig. 11). Drill and fill the lateral cannulated adjustable screw with a 5 in. x 1/8 in. smooth pin to prevent rotation.

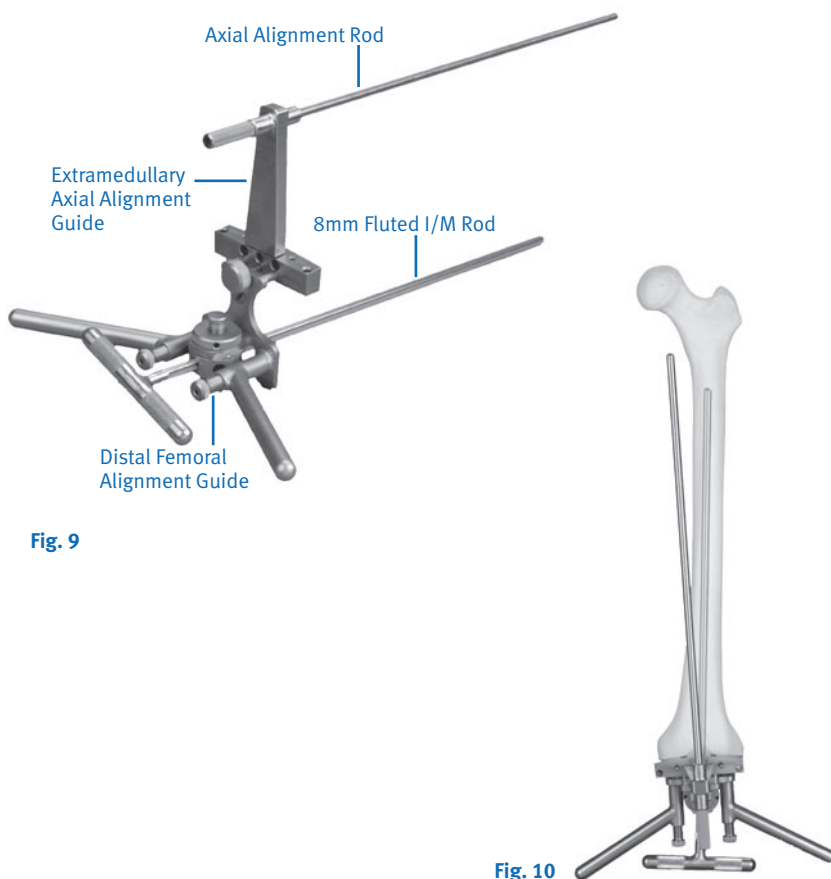


Fig. 9

Fig. 10




Fig. 11

The guide facilitates a cut that is 4-6° valgus from the anatomic axis. This position orients the first cut perpendicular to the mechanical axis. Check the position by attaching the External Alignment Tower, which should be in direct alignment with the femoral head (Fig. 12). Make further minor varus-valgus adjustments by adjusting the threaded screws. Stabilize the cutting block by drilling through the condyles completely and filling the holes with two 3 in. x 1/8 in. smooth pins. Release the thumb-screw from the cutting block, and remove the Distal Femoral Alignment Assembly, leaving the cutting block in place. Alternatively, the Curved Distal Cutting Block with the integral capture can be used in conjunction with the Alignment Guide (Fig. 13).



Fig. 12

Tap the smooth pins flush with the cutting block to eliminate saw impingement and to allow easy removal and replacement of the cutting block (Fig. 13). Cut the distal femoral condyles using a new 1 in. saw blade.

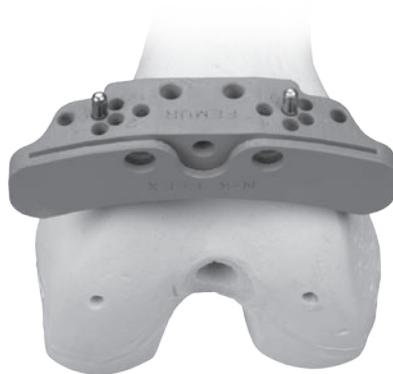

Fig. 13

The $\pm 2^\circ$ Cutting Block can be used to cut the femur from 2-8° of valgus, but it is rarely needed. If using the block, place it over the pins at the 11mm holes. Because all other femoral cuts are based on the distal cut, it must be perfectly flat before the surgery is continued. Use an Auxiliary Cutting Block to check for flatness (Fig. 14).

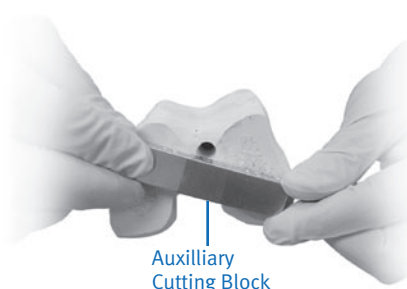


Fig. 14

A central high spot near the intercondylar notch may persist and will require additional planing. The high spot must be eliminated to keep the femoral component from becoming “high centered” when it is implanted. Eliminate the high spot by making a few extra passes with the saw blade using a slight upward spring of the blade against the bone.

Drilling the Distal Femoral Holes and Calibrating the Femur

With the knee maximally flexed, center the *Gender Solutions Natural-Knee Flex Distal Femoral Sizing/Drill Guide* on the femoral condyles. Position the guide by referencing the posterior femoral condyles on the skids, and use the captured set pins to stabilize it (Fig. 15).

Distal Femoral Drill Guide with Sizing Caliper




Fig. 15

If a defective posterior condyle is present, pin the good condyle with the jig, and rotate the opposite posterior skid away from the posterior defect 1mm to 2mm. The drill holes may be set for 3° of external rotation (left or right). To externally rotate the femoral component set the rotation before placing the guide onto the distal femur.

The Distal Femoral Drill Guide also acts as a caliper to determine the correct anterior/posterior femoral size (Fig. 16).

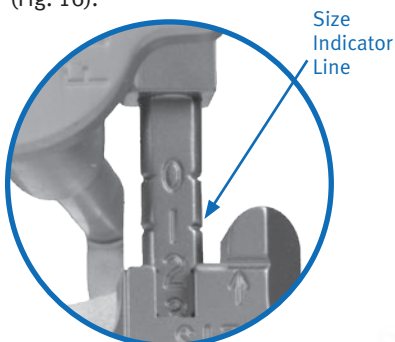


Fig. 16

If the mark falls between sizes, there are three things that can be done to accommodate this situation. First, the MIS 2mm Shift Guide can be placed on the distal femur, referencing the set pin holes from the Distal Sizing/Drill Guide (Fig. 17). As implied, this will shift the reference drill holes for the *Gender Solutions Natural-Knee Flex Femoral Cut Blocks* 2mm anteriorly, thus allowing use of the smaller-sized femoral component.



Fig. 17

Second, the MIS 3° Flexion Block can be used to recut the distal femur in 3° of additional flexion, reducing the risk of femoral notching and allowing the use of the smaller sized femoral component. Third, the larger size is chosen to avoid notching the anterior cortex. When the femoral size is determined the two reference holes are made with the 1/4 in. Stop Drill through the 2mm Shift Guide (Fig. 17) or the Distal Femoral Drill Guide (Fig. 18).




Fig. 18

Finishing the Femur

Place the appropriately-sized *Gender Solutions Natural-Knee Flex* Femoral Finishing Guide into the drilled reference holes as established by the Distal Femoral Sizing/Drill Guide. Additional guide stability is attained by drilling and pinning the 1/8 in. oblique medial and/or lateral holes in the Femoral Finishing Guide (Fig. 19).



Fig. 19

A resection guide (angel wing) can be used to assure the desired resection level will be achieved on the anterior cortex. The cut slots accommodate a saw blade thickness of .050 in. or 1.27mm. The posterior and posterior chamfer cuts can be made with a 1 in. wide blade with the knee flexed at 110°. The anterior and anterior chamfer cuts can then be made with a 1/2 in. wide blade with the knee flexed at 60° (Fig. 20).



Fig. 20

The trochlear recess notch is then created. This can be facilitated by using a 1/2 in. reciprocating saw to make the bottom of the U-shaped notch cut. The notch cut is finished by passing the notch chisel through the trochlear recess with a mallet (Fig. 21). Alternatively, the notch chisel can be inserted into the trochlear recess in the cutting guide in an inverted fashion to make the side cuts of the trochlear recess, followed by passing the notch chisel through the Cutting Guide to finish the bottom of the U-shaped notch cut.




Fig. 21

When all femoral cuts are completed, the finishing guide is removed from the distal femur by first removing the 1/8 in. pins, and inserting the threaded handle into the femoral finishing guide (Fig. 22). The Slaphammer Extractor is inserted into the hole in the Extraction Handle to facilitate removal of the Femoral Finishing Guide (Fig. 23).

Fig. 22

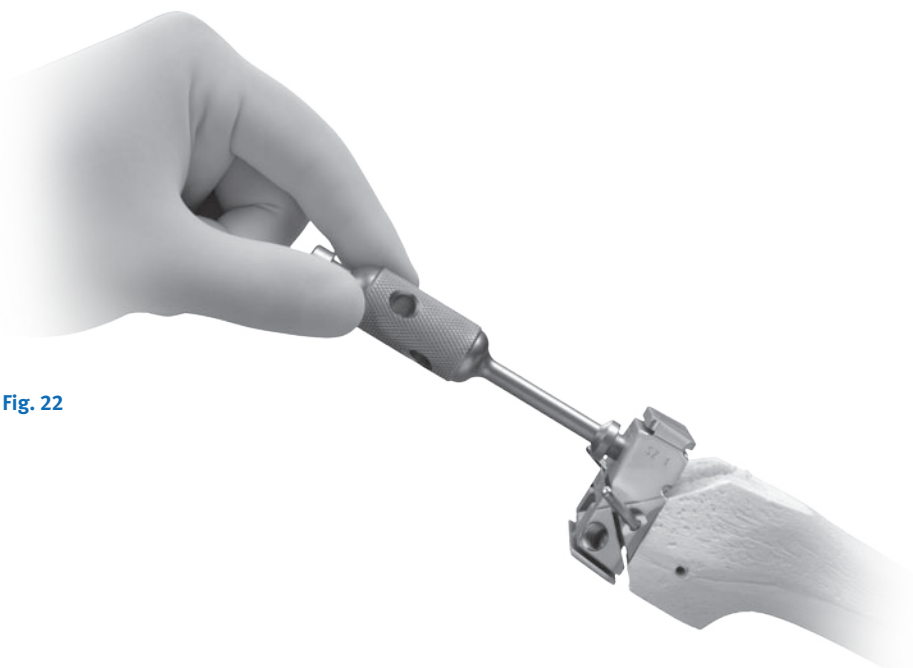
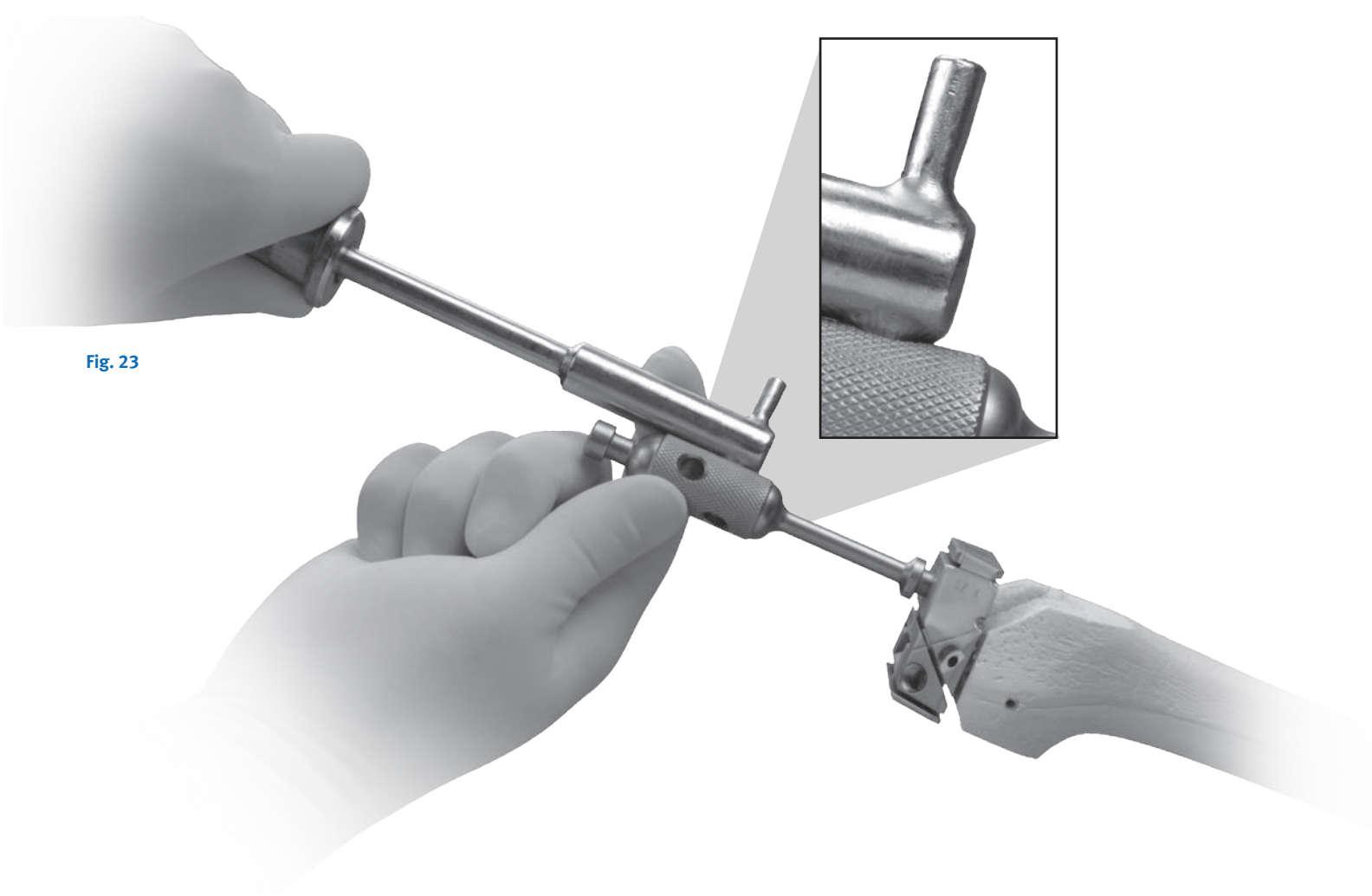


Fig. 23



Optional Method of Finishing the Femur

Making the Anterior and Posterior (A/P) Femoral Cuts

Place the appropriately-sized *Gender Solutions Natural-Knee Flex Open A/P Cut Guide* into the reference holes established by the *Natural-Knee Flex Distal Femoral Sizing/Drill Guide*. A resection guide (angel wing) can be used to assure the desired resection level will be achieved on the anterior cortex. The saw capture for this technique is specific to the *Natural-Knee Flex Open Cut Guides* and accommodates a 1.27mm or .050" saw blade. After completing the anterior and posterior cuts (Fig. 23a), remove the saw capture and use the Slaphammer Extractor to remove the *Natural-Knee Flex Open A/P Cut Guide* (Fig. 23b).




Fig. 23a




Fig. 23b

Making the Chamfer Cuts

Use the appropriately-sized *Gender Solutions Natural-Knee Flex Open Chamfer Cut Guide* to make the anterior and posterior chamfer cuts (Fig. 23c).




Fig. 23c

Initiate the vertical cuts of the notch with a reciprocating saw or an oscillating saw blade, using the chamfer cutting block as a guide (Fig. 23d).



Fig. 23d

Complete the cut using a 1/2 inch saw blade or a 3/4 inch osteotome held flush with the anterior step in the chamfer cutting block (Fig. 23e).




Fig. 23e

Upon completion of the notch cut, place the saw capture on the chamfer block and insert an 1/8 inch pin, coupling the capture to the chamfer block for removal of the chamfer block (Fig. 23f).

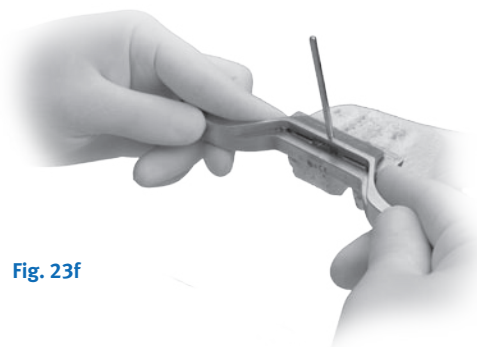

Fig. 23f

Preparing the Proximal Tibia

Maximally flex the knee and excise the anterior cruciate ligament along with any remaining meniscus. Recess the PCL about 8-9mm using a small knife blade. Place the Large Bent-Knee Retractor behind the tibia just lateral to the PCL to sublunate the posterior margin of the tibia anterior to the femur. Place a Smaller Bent-Knee Retractor medially. Place two retractors laterally with one anterolaterally to retract the patellar tendon and fat pad.

Using the Extramedullary Tibial Technique

After adjusting the Proximal Tibial Cutting Guide to the approximate tibial length, place the jig on the tibia and stabilize it by tapping the longest pin into the central tibial plateau on the proximal portion of the guide, just anterior to the tibial spine in the midline (Fig. 24).

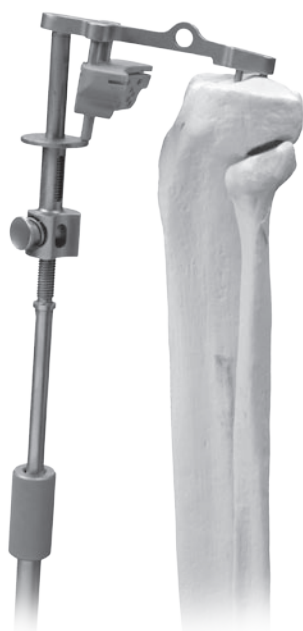

Fig. 24

Setting the Rotation

First, obtain proper rotational alignment by using the tibial tubercle as a guide. Align the distal pin of the cutting block just medial to the tibial tuberosity.

The posterior edges of the proximal tibial plateau should be aligned parallel with the cutting block (Fig. 25). Lock the jig into position by tapping the shorter pin into the proximal tibia.

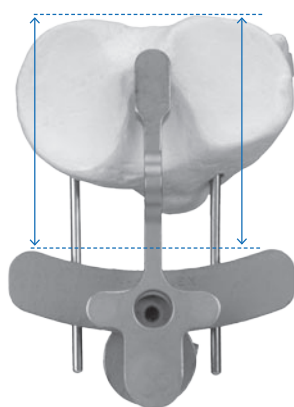


Fig. 25

Setting the Varus/Valgus Angle of the Tibial Cut

In order to achieve a perpendicular cut in the medial/lateral plane, maintain the medial/lateral position of the distal portion of the MIS Extramedullary Guide so that it is in the middle of the ankle (Fig. 26). If the patient has an excessive proximal tibial varus deformity, the varus/valgus angle on the cut block can be adjusted by sliding the distal portion of the MIS Extramedullary Ankle Alignment Guide laterally to create a slightly varus cut, up to approximately 2° to allow for resection of a more symmetrical wedge of proximal tibia. The alignment guide should still fall within the confines of the ankle joint, although it will be slightly (2°) lateralized at the distal tibiofemoral joint (Fig. 27), creating an overall end alignment of 4° valgus instead of 6° valgus.



Fig. 26



Fig. 27

Setting the Posterior Slope

Re-establish the patient's posterior slope by inserting a 5 in. x 1/8 in. smooth pin through the 16mm hole of the cutting block and over the least involved portion of the tibial plateau, or through the hole in the cut slot if using the Curved Cutting Block or with the integral capture.

Reproduce the posterior slope of the proximal tibia by moving the distal portion of the jig anteriorly or posteriorly until the pin is parallel to the proximal tibia (Fig. 28). The posterior tilt of the tibia may range from 4-12°. The goal is to cut parallel to the joint surfaces. Avoid excessive posterior slope especially if the PCL is deficient.

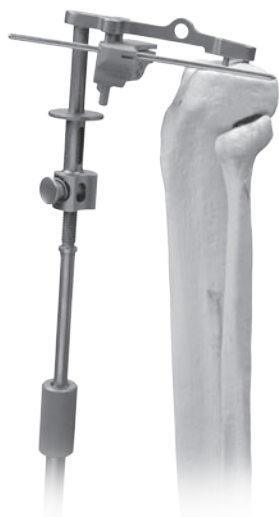

Fig. 28

Level of Resection

Finally, establish the level of the tibial cut by placing the stylus end marked "PRIMARY" over the least-involved weight-bearing portion of the tibial plateau in order to re-create the joint line. The stylus position references a 7mm bone cut. With a varus deformity, the reference point is typically the highest peripheral portion of the lateral

plateau. With a valgus deformity, the reference point is typically the highest portion of the medial tibial plateau.

Cutting the Tibia

Dial down the cutting block until the tip of the stylus has reached good cartilage (Fig. 29).

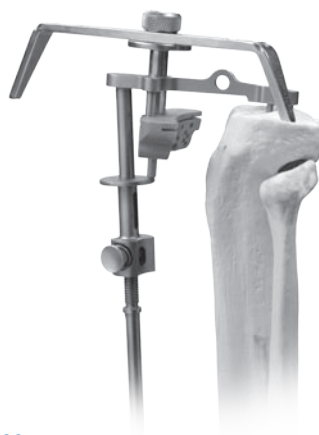

Fig. 29

Stabilize the cutting block by drilling through the 7mm holes and filling them with two 3 in. x 1/8 in. smooth pins. To avoid the drill point skiving off the medial cortex, mark the drilling location through the appropriate drill hole in the Tibia Saw Guide.

Next, take the drill bit outside the saw guide and drill through the cortex at the previously marked spot. Place the drill bit back through the appropriate drill hole and drill through the tibia. Once the cutting block has been stabilized, remove the stylus and the remainder of the Proximal Tibial Cutting Guide using the Slaphammer. Tap the 3 in. x 1/8 in. smooth pins so that they are flush with the cutting block.

In order to verify the varus/valgus angle of the desired tibial cut, place the Tibial Alignment Checker on the cutting block. If the tip of the rod falls in the middle of the ankle (Fig. 31a), then a perpendicular tibial cut will be achieved. If the tip of the rod points to the lateral malleolus, a 2° varus tibial cut will be achieved (Fig. 30b), creating an overall end alignment of 4° valgus instead of 6° valgus.

a. Perpendicular Cut b. 2° Varus Cut



Fig. 30

Most patients require a minimum of 7mm of resection to allow use of at least a 9mm tibial component. Move the cutting block down in 2mm increments to eliminate bone defects and match the thicknesses of the available tibial inserts. Use the small, Angled Knee Retractors to protect the medial and lateral collateral ligaments. If preserving the PCL, the PCL should be well protected with the Large Angled Knee Retractor and a 1/4 in. osteotome. Protect the PCL by placing a small (1/4 in. or 1/2 in.) osteotome just anterior and deep relative to the ligament, in order to prevent the saw blade from going too posterior.

Using a 1 in. saw blade, cut the proximal tibia (Fig. 31).

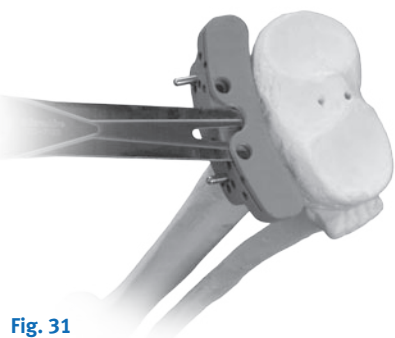


Fig. 31

Measure the resected tibia in areas of relatively normal cartilage using the caliper (Fig. 32).



Fig. 32

Add 1mm to this measurement for bone loss from the saw blade to predict the thickness of the tibial replacement in a PCL sparing procedure, or 2mm if the PCL is sacrificed.

Check the tibial cut for flatness by sighting along the block or by using an Auxiliary Cutting Block as a level (Fig. 33).




Fig. 33

Sizing and Drilling the Proximal Tibia

Position the Proximal Tibial Drill Guides on the cut surface of the proximal tibia and select the largest-sized tibial baseplate that does not overhang. Medial overhang is a recognized source of pes bursitis and should be avoided. To prevent medial overhang, drill the central hole on the medial side to the first mark on the calibrated drill bit and fill it with a 3 in. x 1/8 in. smooth pin. Adjust the final rotation based on the tibial tubercle, and drill and fill the lateral central hole (Fig. 34).

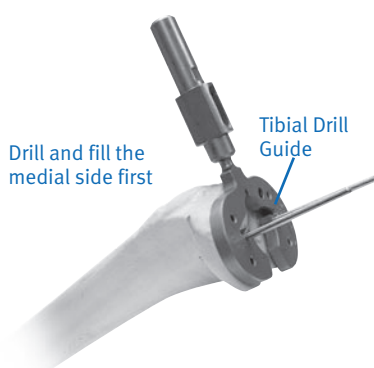


Fig. 34

Check the alignment of the tibial cut by using the Proximal Tibial Drill Guide in conjunction with an alignment rod. Drill the remaining four peripheral holes to the same depth. Stabilize the drill guide by inserting smooth pins through the drilled holes. If a drill hole or one of the four baseplate pegs falls on sclerotic bone, enlarge the hole slightly by toggling the drill bit, as the implant requires that a 4.8mm peg fits into a 3.2mm hole.

Rotating Platform Tibial Preparation

Select and assemble the appropriate sized rotating platform baseplate reamer housing and reamer as designated by the size description on the housing (Fig. 35).




Fig. 35

Attach the reamer housing to the tibial drill guide and align the tab on the end of the reamer with the hole [anterior medial] (Fig. 36). Ream to the stop with power or by hand with the T-handle from the revision instrument set.



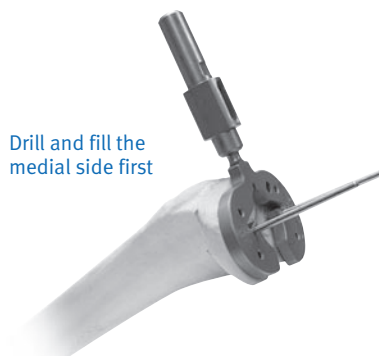Fig. 36

Cruciate-Stemmed Baseplates

Insert and impact the Small (for baseplate sizes 0 and 00), Medium (for baseplate sizes 1 and 2), or Large (for baseplate sizes 3-5) Tibial Broach if a stemmed cruciate tibial component is to be used.

Modular Cemented Tibial Baseplate

Position the Modular Tibial Drill Guides on the cut surface of the proximal tibia and select the tibial baseplate that provides the most coverage without overhanging. Medial overhang is a recognized source of pes bursitis and should be avoided. To prevent medial overhang, drill the central hole on the medial side to the first mark on the calibrated drill bit and fill with a 3 in. x 1/8 in. smooth pin. Adjust the final rotation based on the tibial tubercle, and drill and fill the lateral central hole. Drill the remaining four peripheral holes to the same depth (Fig. 37).



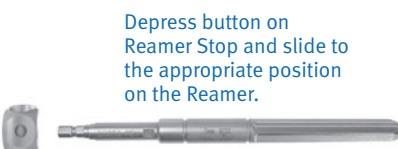
Drill and fill the medial side first

Fig. 37

Check the alignment of the tibial cut using the Modular Tibial Drill Guide in conjunction with an alignment rod. Position the appropriately-sized Modular Tibia Boss Reamer Guide on the Modular Tibia Drill Guide (Fig. 38) and assemble the Modular Tibia Boss Reamer Stop to the Modular Tibia Boss Reamer (Fig. 39).



Fig. 38



Depress button on Reamer Stop and slide to the appropriate position on the Reamer.

Fig. 39

The Modular Tibia Boss Reamer Stop can be positioned on the Tibial Boss Reamer in two positions to prepare for: 1) the baseplate boss only, and; 2) the baseplate with a 14.5 x 75mm stem extension (Fig. 40).



Fig. 40

After positioning the Reamer Stop at the proper position, ream through the Reamer Guide until the Reamer Stop contacts the Reamer Guide shoulder (Fig. 41).

Note: The Reamer Stop should not be assembled from the reamer end in order to avoid dulling the reamer's cutting edges.




Fig. 41

Position the appropriately-sized Modular Tibia Keel Broach on the Modular Tibia Drill Guide and impact (Fig. 42).




Fig. 42

If desired, achieve 2mm of press by impacting the broach to the groove just below the impaction head (Fig. 43).



Fig. 43

Note: If selecting the 14.5 x 75mm stem extension, remove the tip of the Modular Tibia Keel Broach and assemble the stem trial to the keel broach prior to impaction (Fig. 44).



Fig. 44

Preparing the Patella

It may be difficult to prepare the patella with the trial femoral and tibial components in place. The joint will be decompressed after femoral and tibial bone resections and without trials in place to allow eversion of the patellar to at least a 90 degree angle. Place the leg in full extension and stabilize the patella with one or two inverted towel clips or Weber clamps to keep the patella partially everted. Incise soft tissue around the patella down to the insertion of the quadriceps and patellar tendons using an electrocautery knife. Before making any bone cuts, determine the maximum thickness of the patella using a caliper (Fig. 45).



Fig. 45

Using a 1/8 in. drill, drill the highest portion of the medial facet perpendicular to the articular surface approximately 12mm deep (Fig. 46).

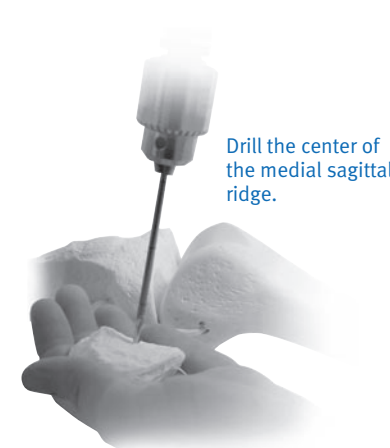


Fig. 46

This acts as a guide for proper medialization of the patella.²⁰ Next, use the Patella Osteotomy Guide with the stylus set for the desired amount of resection (usually 8mm). If the patella is very worn, resect less bone. At least 10mm of bony patella should be retained.

Apply the guide medially and laterally with the jaws at the osteochondral juncture and the handles of the jig oriented toward the foot. The jaws should be parallel to the dorsal surface of the patella. Position the stylus over the most prominent point on the patella. If the 10mm component is countersunk, position the stylus for 7mm of resection. Make the cut with a 1 in. saw blade (Fig. 47).




Fig. 47

20. Hofmann AA, Tkach TK, Evanich CJ, Camargo MP, Zhang Y. Patellar component medialization in total knee arthroplasty. J Arthroplasty. 1997 Feb; 12(2): 155-60.

Using the Sizing Template (Fig. 48), select the maximum-sized patella that does not overhang (sizes 0 to 3). Eccentric placement of the patella 3-4mm toward the medial facet allows for better tracking. Use the 1/8 in. drill hole as a reference for proper medialization.

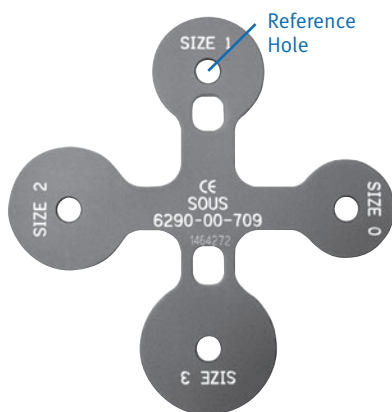


Fig. 48

Place the Patellar Clamp with the appropriately-sized Patella Bushing over the cut surface of the patella and center it slightly toward the medial facet and over the 1/8 in. drill hole (Fig. 49).



Fig. 49

Prepare the surface by applying gentle pressure with the matching sized cutter (Fig. 50) for 5-10 seconds at a time until the desired thickness is achieved.



Fig. 50

Place the caliper through the inferior hole of the Patella Clamp and over the Patella Bushing (Fig. 51).



Fig. 51

Warning: Do not countersink the 8mm All-Poly Patella.

If the 10mm metal-backed component is selected, it should be recessed 2-3mm.

Example: If the patellar thickness is 25mm, the thickness will be 17mm after resection. The final thickness of the countersunk area should be 15mm for use with a 10mm-thick patellar component.

With the clamp still in place, insert the Drill Guide into the Patella Bushing (Fig. 52).

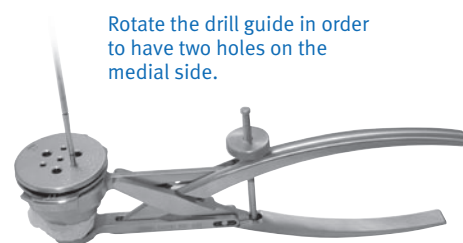


Fig. 52

Each hole must be drilled and filled before proceeding to the next hole to ensure an equal distance between holes. Use the All-Poly Patella Stop Drill to drill the three larger holes. The peg holes are in the same location on all of the patellar sizes.

Separate patella trials are available for 8mm and 10mm all-poly patellae, as well as for the metal-backed patellae.

Trial Reduction

Prior to trial reduction, remove any posterior osteophytes on the femur using a 3/4 in. Curved Osteotome while lifting the femur with a bone hook. Osteophyte removal is required for maximum knee flexion.

The tibial baseplate trial is applied first. The decision to use either the rotating platform or the fixed bearing can now be made. To determine if the rotating platform is desired, place the appropriate size rotating platform articular surface provisional adapter onto the tibial baseplate provisional (Fig. 53a). A 9mm or larger rotating platform articular surface provisional is then inserted followed by the appropriate femoral provisional (Fig. 53b). Perform a range of motion to determine stability.



Fig. 53a



Fig. 53b

The rotating platform can be converted to the fixed bearing insert by removing the rotating platform articular surface provisional and articular surface provisional adapter and replacing them with the fixed bearing articular surface provisional. Insert the appropriate femoral provisional (Fig. 54).

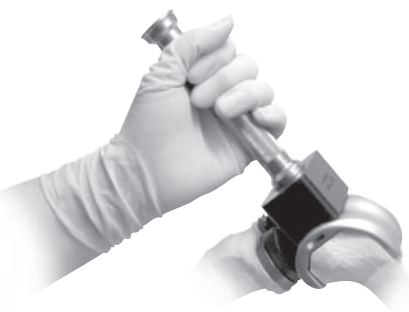

Fig. 54

Note: Both GSF and GSM femoral provisionals should be available to provide for the best fit.

Note: During the trial reduction, observe the relative position of the Femoral Provisional on the tibial Articular Surface Provisional by using the lines on both provisionals. The lines can be used to determine if posterior rollback is occurring, whether the PCL is functional, and if the femoral component will contact the tibial articular surface in the proper location. If the PCL is properly balanced, the Femoral Provisional should sit near the anterior or center lines on the tibial Articular Surface Provisional in extension (Fig. 55a) and near the posterior line in flexion (Fig. 55b).



Fig. 55a



Fig. 55b

If the Femoral Provisional sits posterior to the lines, the PCL may be too tight or the articular surface may be too thick. If the Femoral Provisional sits anterior to the lines, the PCL may be too loose or the articular surface may be too thin.

Any fine-tuning of soft tissue releases should be done at this time (see Soft Tissue Balancing section). Check stability in full extension, 20° of flexion, and full flexion. If the PCL is intact, slight medial and lateral laxity should be allowed. Full extension must be obtained on the operating table. If the PCL is absent, select one size thicker for the articular surface. The slight flexion deformity this creates will stretch out over the first 6 months. It is suggested that the PCL be resected intentionally if the patient has more than 10° varus or valgus deformity or more than a 10-15° flexion contracture preoperatively.

Use an ultracongruent articular component for a PCL deficient knee.

With the leg in full extension, hold the alignment rod (two pieces assembled together) between the center of the ankle and approximately 2cm medial to the anterior superior iliac spine.

This positioning allows the alignment bar to fall at the center of the knee. Remove the provisionals. Remove the Femoral Provisional by inserting the Slaphammer Extractor Tool between the condyles (Fig. 56).



Fig. 56

Implanting the Components

Note: Prior to closure, the surgical site should be thoroughly cleansed of bone chips, bone cement, and any other debris. Foreign particles at the articular interface may cause excessive wear.

Precaution: Zimmer recommends that *Natural-Knee II Porous Tibial baseplates* used without bone cement and with supplemental screw fixation be used with tibial articular surfaces manufactured from highly crosslinked polyethylene.

Pressfit Fixed Tibial Baseplate

Press the tibial baseplate onto the proximal tibia using the Tibial Baseplate Impactor (Fig. 57) after a bone paste slurry has been applied to the tibial surface.



Fig. 57

The tibial baseplate is further stabilized with 50mm x 6.5mm titanium cancellous bone screws (Fig. 58). Use the screws with slight central angulation medially and 10° central angulation laterally. Keep the screws inside the cortex to avoid soft tissue impingement.



Fig. 58

Pressfit Rotating Platform Tibial Baseplate

Press the rotating platform tibial baseplate onto the proximal tibia using the tibial baseplate impactor (Fig. 59) after a bone paste slurry has been applied to the tibial surface.



Fig. 59

Cemented Tibial Baseplate

Apply a 3-4mm layer of bone cement to the underside of the tibial component. Impact the tibial component onto the tibial surface, pressurizing the cement into the bone.

If the 14.5 x 75mm Stem Extension is to be used, remove the baseplate's distal plug by unscrewing the "captured" stem/plug screw from the central portion of the superior side of the baseplate with the Hex-Head Screwdriver (Fig. 58). The Stem Extension is then impacted onto the tibial baseplate using the Stem Impactor and the baseplate "captured" screw is tightened using the 4.5mm Hex-Head Screwdriver.



Fig. 60

Tibial Insert Fixed Bearing

Position the polyethylene insert of the chosen thickness on the tibial baseplate and pushing the articular surface posteriorly by hand to engage the posterior tabs (Fig. 57). If the posterior tabs are not fully engaged, the locking features of the articular surface may be damaged. (Fig. 61).

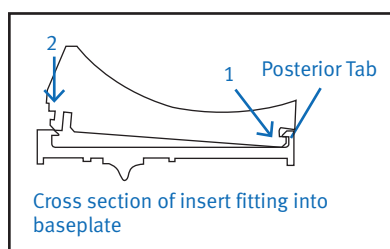
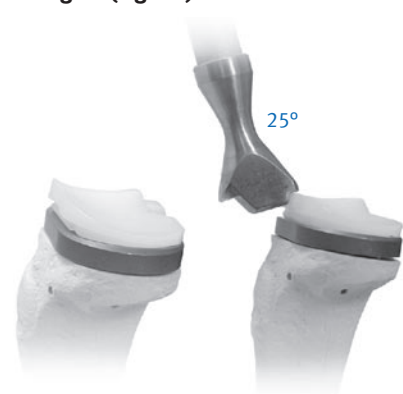


Fig. 61

Position the face of the Impactor Head so that the CONG or ULTRA marking faces the marking on the impaction surface of the insert to be impacted. Orient the Flex Tibial Insert Impactor on the anterior proximal face of the tibial insert at a 25° angle and impact. **Soft tissue must be cleared away to allow for easy insertion.**

A secondary step is suggested to fully engage the medial and lateral ribs on the *Gender Solutions Natural-Knee Flex Tibial Articular Surfaces*, especially on thinner articular surfaces. The Flex all-poly impactor is used to tap the *Gender Solutions Natural-Knee Flex Tibial Articular Surface* on the medial and/or lateral edges (offset from bearing surface center line) to press-fit the ribs into the baseplate.



The gap between the articular surface and the baseplate rim should be uniform on the medial and lateral sides of the components.

Tibial Insert Mobile Bearing

If the rotating platform is selected, the rotating platform polyethylene insert of the chosen thickness is placed onto the baseplate (Fig. 62).

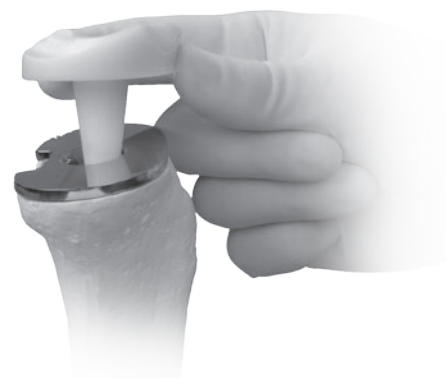

Fig. 62

Note: Do not use *Natural-Knee II Articular Surface Components* or patellae with *Gender Solutions Natural-Knee Flex Femoral Components*. Also, do not use *Natural-Knee II Femoral Components* with *Natural-Knee Flex articular surfaces* or patellae. They were not designed to be compatible.

Femoral Component

Implant the femoral component using the Femoral Impactor (Fig. 63). Check the range of motion and ligament stability again.



Fig. 63

Patella

Implant the patella initially by using the Patella Clamp in combination with the Patellar Inserter (Fig. 64). Ensure final component seating by lightly tapping the mallet on the Inserter.



Fig. 64

Final Steps

Take the knee through the range of motion to observe patella tracking, after letting the tourniquet down. Perform a lateral release if the patella tracks laterally. With the outside-in technique, flex the knee to titrate any necessary release. Make an attempt to save the lateral superior geniculate artery and to keep the synovium intact. Release the tourniquet prior to closure. Insert a large (1/4 in.) drain for 48 hours.

Postoperative Care

Apply a long-leg surgical support stocking over a sterile occlusive dressing. Start continuous passive motion (CPM) at 0-40 degrees, and advance a minimum of 10 degrees every eight hours. Allow hospital discharge when the patient is independent in transfers and ambulation. Most patients are discharged on a home exercise program. Protected weight bearing is recommended for approximately six weeks or until good quadriceps control is present. The patients with a subvastus muscle sparing approach can usually advance to a cane by three weeks. A cane is then used until the patient can walk without a limp. Most patients are walking without assistive devices between six and twelve weeks after surgery.

Intramedullary Tibial Option

Finding the Reference Hole

Drill a 1/4 in. hole in the proximal tibia centering from medial to lateral on the tibial plateau. Anterior/posterior positioning should fall between the middle and anterior one-third of the tibial plateau (Fig. 65).

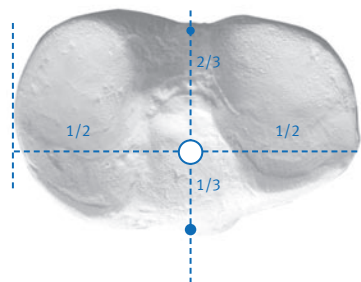


Fig. 65

Slowly insert the 1/4 in. Fluted Intramedullary Rod to locate the medullary canal. Remove the rod and reinsert it through the preassembled Intramedullary Guide, which consists of the Alignment Guide, the Saw Guide, and Tibial Stylus (Fig. 66).

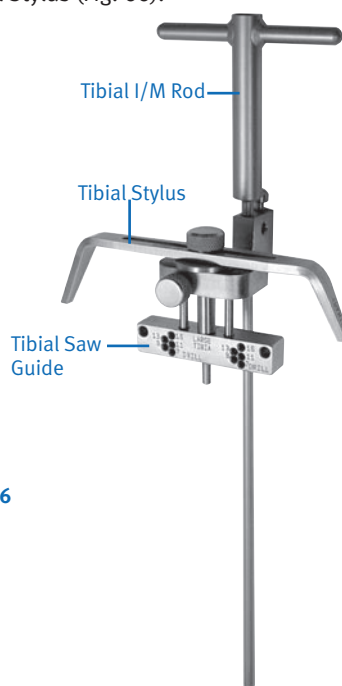


Fig. 66

Setting the Rotation

Adjust rotational alignment using the tibial tubercle. Position the distal pin of the cutting block just medial to the tibial tubercle (Fig. 67).




Fig. 67

The posterior surface of the cutting block should be parallel to the posterior edge of the tibial plateau (Fig. 68).




Fig. 68

Ideally, use both references mentioned above. Lock rotation into place by impacting the set pin with a mallet (Fig. 69). Additional stability can be obtained, if necessary, by drilling and pinning through the auxiliary hole located anteriorly.

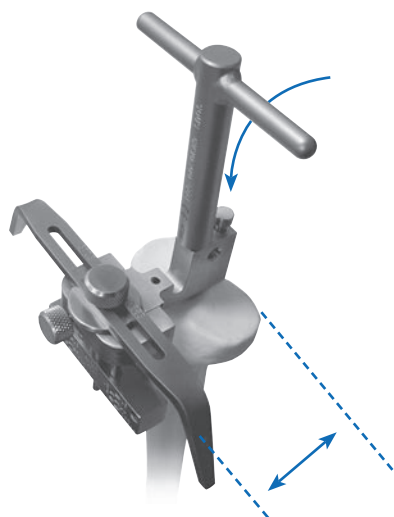


Fig. 69

Setting the Posterior Slope

Place a 5 in. x 1/8 in. pin through the 16mm hole on the cutting guide over the least-affected plateau to achieve replication or through the hole in the cut slot if using the Curved Cutting Block with the integral capture. Adjust the thumb screw on the anterior side of the guide until the pin touches both the anterior and posterior rims of the proximal plateau. When the desired slope has been achieved, remove the 5 in. x 1/8 in. pin (Fig. 70).



Fig. 70

The posterior slope is set at 5° when the black line on either side of the fixed part of the guide is parallel with the posterior aspect of the swivel part of the guide (Fig. 71).



Fig. 71

Setting the Level of Resection

Place the stylus end marked "PRIMARY" over the least-involved weight bearing portion of the tibial plateau to re-create the joint line.

Stabilize the cutting guide by drilling and pinning through the 7mm medial and lateral holes of the cutting guide (Fig. 72).




Fig. 72

Remove the Stylus and Intramedullary Rod to disassemble the Jig (Fig. 73).

A slaphammer helps to remove the Intramedullary Rod and Jig, leaving the Saw Guide fixed to the anterior face of the tibia.




Fig. 73

Using the Tibial Spacer Option

Preparing the Tibia

Tibial spacers address medial and lateral tibial defects (and both 4mm and 8mm modular spacers are available).

Bony defects greater than 9mm of the medial or lateral tibial plateau require a minimum 9mm osteotomy. Tibial spacers correct the deformity without requiring additional bone resection.

After standard preparation of the proximal tibia, assemble the Spacer Cutting Guide and Alignment Plate for sizes 00 and 0, sizes 1 and 2, or sizes 3, 4 and 5 tibias. Set the assembly for medial or lateral and left or right using the reference marks on the end of the Spacer Alignment Plate (Fig. 74).



Fig. 74

Stabilize the Alignment Plate using three smooth pins placed in the nondefective tibial plateau surface previously drilled with the Proximal Tibial Drill Guide. For added stability, place at least one pin through one of the holes located anteriorly on the Spacer Cutting Guide (Fig. 75).




Fig. 75

Make a vertical osteotomy using a calibrated 1 in. saw blade (Fig. 76). This saw cut is either 4 or 8mm deep, depending on the size of the defect. Leave a free saw blade imbedded in the bone to avoid undercutting the uninvolved tibial plateau surface when the horizontal osteotomy is performed.



Fig. 76

The horizontal portion of the step cut is then made through the 4 or 8mm slot, depending on the size of the defect (Fig. 77).




Fig. 77

Trialing the Tibia

Assemble and insert the Trial Spacer and the Trial Tibial Baseplate (Fig. 78). Select the Tibial Trial Insert based on flexion and extension stability and the measured thickness of the tibial wafer of bone.

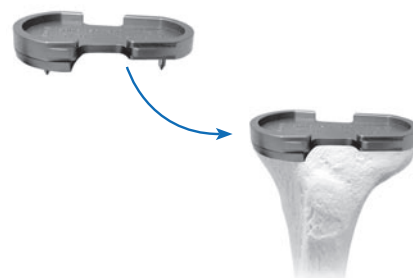

Fig. 78

Implanting the Tibia

Secure the Metal Spacer Implant (4 or 8mm) to the underside of the Final Prosthetic Tibial Metal Baseplate using a threaded peg-and-screw combination, or methyl-methacrylate bone cement (Fig. 79a).

Place the composite on the prepared surface of the tibia and secure it in place (Fig. 79b).

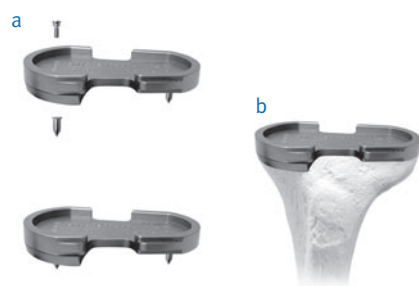


Fig. 79

Balancing the Soft Tissue

Varus Deformity

A varus deformity is easier to correct than a valgus deformity because most of the soft tissue balancing is done with the usual surgical approach to the knee. When the knee is exposed and being prepared for arthroplasty, the medial soft tissue must be released back to the posteromedial corner. This usually releases enough soft tissue initially so that the cuts of the femur, tibia and patella can be made and the final soft tissue balancing can be done with the trial components. Typically, if the knee has less than 10° of varus deformity, the normal medial release done to expose the tibia is enough to correct the deformity. A slight amount of lateral laxity is acceptable since a varus knee will frequently have a stretched-out lateral soft tissue sleeve. The dynamic nature of the lateral side, including the biceps and iliotibial band, eliminates any clinical consequence.

With the posterior cruciate ligament (PCL) intact, the knee should come to full extension. Check this by placing a hand on the greater trochanter. Medial/lateral stability in full extension should have 1mm of laxity. The normal knee has 7° of varus/valgus play. Always test the competence of the PCL by performing a forced posterior draw maneuver. If excessive femoral roll-back in flexion is present, the PCL should be progressively released from the tibia.

In the case of a varus knee that has a significant flexion contracture (greater than 15°), the PCL most likely will require resection. If the PCL is resected, the knee is balanced so that the collateral ligaments have no laxity and the knee rests with 5° to 10° of spring short of full extension. One size/thickness larger tibial insert than the measured amount of bone resection should be implanted. For example, if 9mm of tibia is resected, use an 11mm insert. The posterior capsule will stretch out over the first six months. If the knee lacks full extension, but excessive roll-back is not present in flexion, one can alternatively resect more distal femur (or proximal tibia) by using the +2mm, 2mm, or -4mm block (auxiliary distal femoral saw guide), rather than resecting the PCL. Approximately 1mm of bone resection is required for every 4° of contracture.

Valgus Deformity

Valgus deformities are more difficult to properly balance than varus deformities. A valgus deformity frequently has a stretched out medial collateral ligament that can be difficult to tighten. In many cases it will be easier to balance between medial and lateral if the PCL is resected.

This will allow overstuffing the joint by one insert thickness, which will slightly tighten the medial side. Valgus knees are a frequent indication for use of the ultracongruent components, which provide increased anterior/posterior stability as well as rotational stability. Alternatively, if there is greater than 1cm of difference between varus and valgus laxity, the superficial medial collateral ligament should be advanced distally on the tibia and stabilized with a ligament staple.

Perform lateral soft tissue releases in the following sequence: the popliteus tendon is taken at the time the lateral meniscus is removed. While removing posterior osteophytes, the posterior capsule is released from the femur, which should help with posterolateral tightness. The trials are then placed and the other lateral structure palpated for tightness. If the knee is tight laterally in extension and not flexion, this is due to a tight iliotibial band. The iliotibial band is released from the inside by simply feeling the tight portion of the iliotibial band and transversely sectioning it with a knife while the knee is in full extension. If care is taken to keep all of the release anterior to the head of the fibula, the peroneal nerve should be well protected.

If the knee is tight in both extension and flexion, the lateral collateral ligament is usually tight. This can be confirmed by placing a finger in the lateral gutter of the knee and palpating the lateral collateral ligament to determine if it is too tight. With the knee in flexion, release the lateral collateral ligament flexion by peeling the lateral collateral ligament subperiosteally off its origin on the femur to allow it to slide distally. The lateral collateral ligament can be released partially or completely in continuity with the lateral posterior capsule. Another option is to do a Z-lengthening of the fibular collateral or the iliotibial band. In extreme cases of valgus deformity, the biceps tendon may need to be released through a separate incision.

Ultracongruent Component Patient Selection

1. Marked valgus deformity - requiring PCL and lateral soft tissue release.
2. Prior high tibial osteotomies - soft tissue balancing is the same as for a valgus deformity with lateral soft tissue and PCL release.
3. Patellectomy - PCL incomplete or absent.
4. Most revision situations - PCL deficient or nonfunctional.

Note: The Ultracongruent Insert Component should not be used if the PCL is present.

Contact your Zimmer representative or visit us at www.zimmer.com



Lit.No. 06.01733.012 – Ed. 09/2009 ZHUB



+H84406017330121/\$0909011098